

## **Case Report**

# **Osseous Hydatid Disease**

**\*Maliheh Metanat<sup>1</sup>, Batool Sharifi-mood<sup>1</sup>, Mahnaz Sandoghi<sup>2</sup>, Roya Alavi-Naini<sup>1</sup>**

<sup>1</sup> *Research Center for Infectious Diseases and Tropical Medicine, Zahedan University of Medical Sciences, Boo-Ali Hospital, Zahedan, Iran*

<sup>2</sup> *Rheumatology Dept. Zahedan University of Medical Sciences, Zahedan, Iran*

(Received 16 May 2008; accepted 15 Oct 2008)

### **Abstract**

A 48-year-old man referred with pain and swelling at the upper and middle third of left tibia with a history of previous osseous hydatid disease three years ago. Despite surgical procedure which was performed in this case, recurrence was observed and repeated exploration with wide resection and oral medical therapy were recommended. Bone hydatid cyst is an uncommon disease with difficult response to treatment. Hydatid disease should be included in the differential diagnosis of cystic lesions of bone in endemic regions.

**Keywords:** Hydatid cyst, Tibia, Recurrence, Iran

### **Introduction**

Hydatidosis is a parasitic disease caused by *Echinococcus granulosus* by the development of the parasite's larval in man (1, 2). All parts of the body may be involved, but the liver and lungs are the main locations of the disease. The bone infection is rare, accounting for 0.5 to 2.5% of all hydatid lesions (3, 4). Patients usually are asymptomatic and present at an advanced stage of the disease, when lesions have become extensive. Hydatid bone disease is not easy to eradicate and may be impossible to cure (4, 5). Here we report a case of this rare entity of an isolated hydatid cyst of the tibia.

### **Case Report**

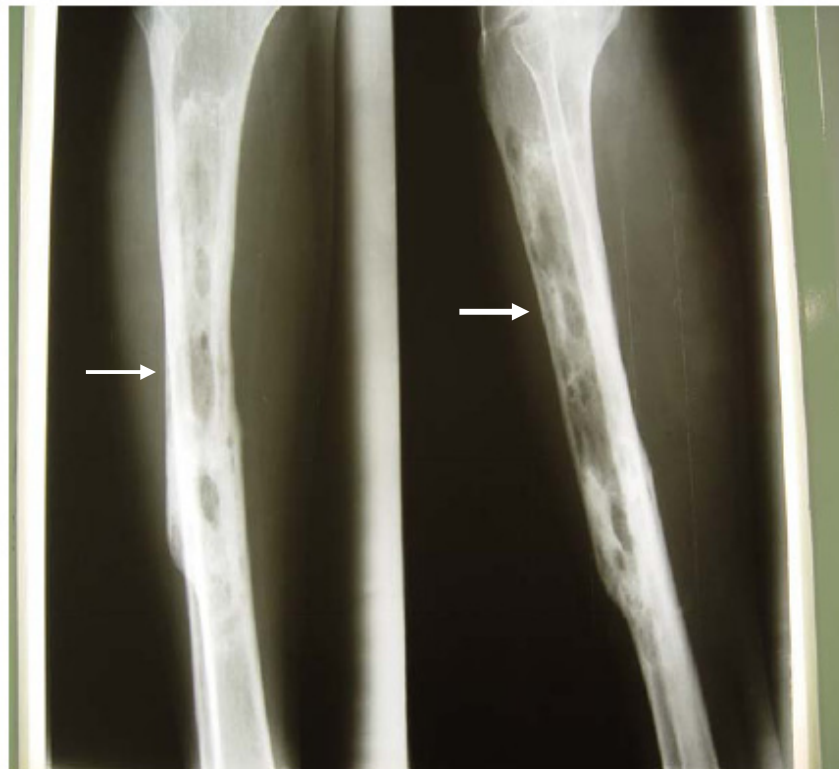
In December 2006, a 48-year-old man was admitted to Boo-Ali Hospital (a University Hos-

pital in Zahedan, Southeast of Iran) and was complaining of pain in his left tibia. He had a history of taking care of animals such as sheep and dog. His past medical history was unremarkable, but he had a history of a pathological fracture in three years before. At that time, radiographs showed signs of osseous hydatid disease including lucent lesions in the left tibia that was associated with bone expansion and thinning of the cortex. Pathological results confirmed the hydatid cyst. He underwent surgery where curettage was done. Then, he was treated with albendazole but he discontinued his treatment after two weeks. After 3 years, he was admitted for recurrent tenderness and swelling at the upper and middle third of tibia without any general symptoms. Physical examination revealed a fluctuating mass with a diameter of 2×3 cm in the left tibia. Radiographs revealed an old fracture with multiple oval cysts (2.5 cm to 5 cm. in a mean diame-

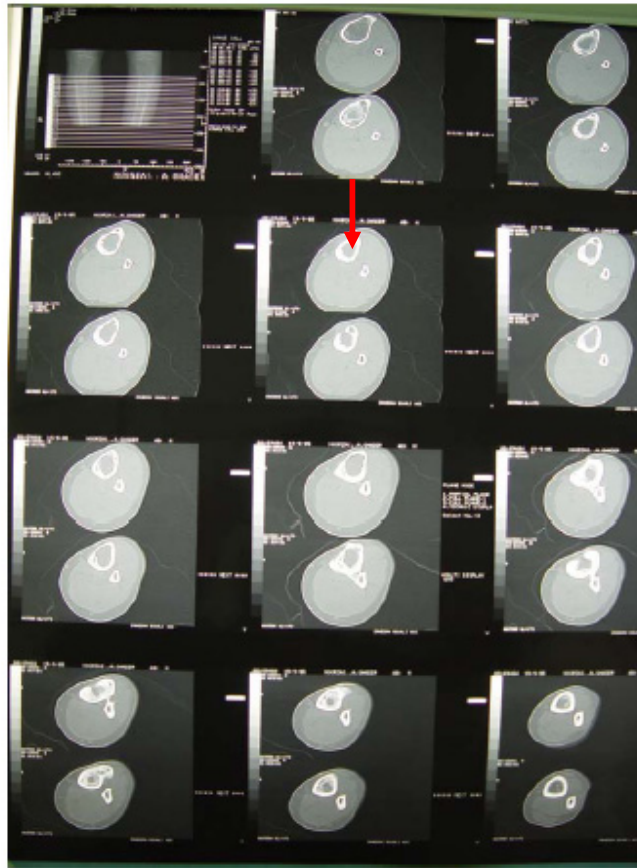
ter), located in the diaphyseal part of the tibia (Fig. 1).

Computed tomographic (CT) scan revealed hypodense bone lesions with sclerosis and defect of cortex of the left tibia. A periosteal reaction was evident in the cortical area (Fig.2). No significant abnormalities were found on CXR. The brain CT- scan was normal. The sonography of the abdomen and pelvic had no findings of abnormality. The laboratory investigations revealed Hgb 13.7 g/dl; WBC 4000 (Neutro, 60% and Lymph, 40%); ESR 14mm/hr; Alt 46; Ast

29; Alkpho 160; total bili 0.5 and U/A normal. Clear fluid was aspirated from the abscess, and the sample was sent for microbiology studies. The microscopy report confirmed the diagnosis. The lower extremity was casted and immobilized. Oral therapy with albendazole (800 mg /day) was prescribed at one cycle before surgery and recommended for 4 courses after resection. Repeated exploration with wide resection and oral therapy was necessary. At this time, he was referred to the other hospital for surgery.



**Fig. 1:** Anteroposterior and lateral radiograph of left tibia showing cystic lesions (arrow) with old fracture



**Fig. 2:** Computed tomographic (CT) scan showing hypodense bone lesions (arrow) with sclerosis and defect of cortex of left tibia

## Discussion

Primary bone location is very rare, accounting for 0.5- 2.5% of all hydatid lesions (1). Extras-pinal locations are even rarer (6). However, there are some reports about hydatid disease in humerus, femur, hip, scapula, rib, iliac, tarsal bones, and tibia (6-14). Sapkas *et al.* reviewed 8 cases of hydatid bone disease in different anatomical locations with follow-up periods from 4 to 16 years, and discussed many related diagnostic and therapeutic problems (1). Hydatid bone disease is often asymptomatic, and is therefore usually diagnosed at an advanced stage (15), as in the present case. The initial location of the lesion in long bones is metaphyseal or epiphyseal, later extending to the

diaphysis. Diagnosis is primarily based on findings of X-ray and CT scans. X-ray findings include monolocular, bilocular, or multilocular cysts. Monolocular cysts, as in this case, are rarely observed and are characterized by their oval or polycyclic nonspecific lacunae of variable sizes. Progression of the disease takes place in 2 forms: formation of diverticuli and exogenous vesiculation (16, 17). Potential complications include pathological fracture, infection, and fistulization of the abscess. The present case experienced pathological fracture and fistulization of the abscess.

Hydatid bone disease should be considered in the differential diagnosis of osteolytic lesions, especially in endemic areas. Differential diagnoses include chronic osteomyelitis, fibrous dysplasia of bone, osteosarcoma, and benign

cystic lesions. The presence of a periosteal reaction, osteosclerosis, and calcification are not specific for hydatid bone disease (15, 18).

The present case of hydatid bone disease was not suspected preoperatively, and the immunological tests such as haemagglutination and total and specific immunoglobulin E level measurements were not performed, although they are recommended in the literature as preoperative diagnostic parameters (1, 15).

Surgery is the treatment of choice for hydatid bone lesions. Many authors have advocated wide resection of the involved bone along with the surrounding soft tissue as the only definitive treatment of the condition (4) with or without chemotherapy using albendazole or mebendazole (9). Natarajan *et al.* (2) emphasised on the need for complete surgical extirpation of the cyst. Curettage and deep radiotherapy have been reported to be insufficient (19). Despite the limited surgical procedure which was performed in this case, 3 years ago, recurrence was observed and repeated exploration with wide resection was necessary.

Conclusively hydatid bone disease is a rare disease that treatment is difficult and recurrence is common. A high index of suspicion is necessary for its diagnosis, especially in patients who live in or travel to sheep-raising areas where hydatid disease is endemic.

## Acknowledgments

We would like to thank Mrs Batool Namroodi and Saideh Metanat for collecting of data.

## References

1. Sapkas GS, Stathakopoulos DP, Babis GC, Tsarouchas JK. Hydatid disease of bones and joints. 8 cases followed for 4-16 years. *Acta Orthop Scand.* 1998; 69(1): 89-94.
2. Kalinova K, Proichev V, Stefanova P, Tokmakova K, Poriázova E. Hydatid bone disease: A case report and review of the literature. *J Orthop Surg (Hong Kong).* 2005; 13(3):323-5.
3. Natarajan MV, Kumar AK, Sivaseelam A, Iyakutty P, Raja M, Rajagopal TS. Using custom mega prosthesis to treat hydatidosis of bone: a report of 3 cases. *J Orthop Surg (Hong Kong).* 2002;10(2): 203-5.
4. Mnaymneh W, Yacoubian V, Bikhazi K. Hydatidosis of the pelvic girdle- treatment by partial pelvectomy: A case report. *J Bone Joint Surg Am.* 1977;59(4): 538-4.
5. Charles H King. Cestodes. In: Mandell, Douglas, Benetts, editors. *Principles and practice of infectious diseases*, Churchill Livingstone; 2005. p: 3285-3299.
6. Herrera A, Martinez A. Extrapinal bone hydatidosis. *J Bone Joint Surg Am.* 2003; 85(9):1790-94.
7. Bauer T, Daivid T, Lortat-Jacob A. Extensive hydatid disease of the femur: a case report. *Med Mal Infect.* 2004;34(4):177-9.
8. Tomos P, Kakaris S, Lachanas E, Karakatsani A. Secondary echinococcosis of the rib and soft tissues. *Respiration.* 2005;72(5):542.
9. Aslan B, Aslan G, Ozardali I. Multilocular echinococcosis in humerus: a case report. *J Egypt Sco Parasitol.* 2001; 31(3): 961-2.
10. Papanikolaou A, Antoniou N, Pavlakis D, Garas G. Hydatid disease of the tarsal bones: a case report. *J Foot Ankle Surg.* 2005; 44(5): 396-400.
11. Arti HR, Yousofi-Darani H. Fibular hydatid cyst, *Indian Journal of Orthopaedics.* 2007; 41(3):244-45.
12. Fakoor M, Marashi- Nejad SA, Maraghi S. Hydatidosis of tibia, *Pak J Med Sci.* 2006; 22(4): 468-470.

13. Omidi Kashani F, Hagi Z, Mazioumi M. Unusual presentation of iliac bone hydatid cyst, Iran J Med Sci. 2007;32(2):121-123.
14. Ebrahimi A, Assadi M, Saghari M, Eftekhari M, Ghasemikhah R, Assadi S. Whole body bone scintigraphy in osseous hydatidosis: A case report. J Med Reports. 2007; 1:93.
15. Zlitni M, Ezzaouia K, Lebib H, Karray M, Kooli M, Mestiri M. Hydatid cyst of bone: diagnosis and treatment. World J Surg. 2001;25(1):75-82.
16. Markakis P, Markaki S, Prevedorou D, Bouropoulou V. Echinococcosis of bone: clinico-laboratory findings and differential diagnostic problems. Arch Anat Cytol Pathol. 1990;38(3):92-4.
17. Saidi F. Hydatid cysts of bone. In: Saidi F, editor. Surgery of hydatid disease. London: WB Saunders. 1976;135-8.
18. Torricelli P, Martinelli C, Biagini R, Ruggieri P, De Cristofaro R. Radiographic and computed tomographic findings in hydatid disease of bone. Skeletal Radiol. 1990;19(6):435-9.
19. Engin G, Acunas B, Rozanes I, Acunas G. Hydatid disease with unusual localization. Eur Radiol. 2000;10(12):1904-12