



Tehran University of Medical
Sciences Publication
<http://tums.ac.ir>

Iran J Parasitol

Open access Journal at
<http://ijpa.tums.ac.ir>



Iranian Society of Parasitology
<http://isp.tums.ac.ir>

Case Report

A Therapeutic Side Effect on Hydatid Cyst after Lung Cancer Treatment: A Case Report

Cebraail Akyuz¹, *Kadir Çorbacı²

1. Department of General Surgery, University of Health Sciences, Haydarpaşa Numune Training and Research Hospital, Istanbul, Turkey
2. Department of General Surgery, Bilecik Şeyh Edebali University, Faculty of Medicine, Bilecik, Turkey

Received 11 Nov 2025 Accepted 10 Feb 2026	Abstract Cystic echinococcus (CE) is an important health problem affecting societies living especially in rural areas. Our patient was a 64-year-old male who received PAIR treatment and albendazole treatment for CE at Haydarpaşa Numune Training and Research Hospital, Istanbul, Turkey between 2022 and 2025. The patient was first operated on for lung cancer. After treatment, the patient continues to live asymptotically in the 36-month follow-up. We observed and followed up that the paxlitaxel and carboplatin treatments received by our patient caused regression in the CE lesions. We think that the effectiveness of this situation should be evaluated first with experimental studies.
Keywords: Chemotherapy; Cystic echinococcus; Positive side effect; Treatment	
*Correspondence Emails: kadir.corbaci@bilecik.edu.tr	

Introduction

The incidence of *Echinococcus granulosus* in endemic areas varied between 1-200 in 100,000 (1). The mortality rate of Cystic echinococcus (CE) was 2-4%, but management of the disease was very important (2, 3).

In complicated cases, rapid progression leading to anaphylactic shock and death was observed (4).

Today, the main treatment method for hydatid disease (HD) was still surgery (1, 5, 6). Despite the effectiveness of surgery, alternative methods were still needed in risk groups and the aim was to avoid the morbidity of surgery. For this reason, PAIR (Puncture, Aspiration, Injection, Respiration) and albendazole treat-



ment were used as alternatives to surgery today (7-9).

In addition, many studies were conducted to test new treatments for the disease in a laboratory environment and to increase alternative treatments to surgery. The effectiveness of new active substances was tested in vitro and on animal models, promising results were obtained (10, 11). Developments were also reported in the field of nanotechnology and targeted treatments (12).

There were experimental studies on the anticancer effects of albendazole group drugs (13). These studies led the literature to question whether anticancer drugs could be used in the treatment of CE. An experimental study reported the anthelmintic effect of 5-fluorouracil and paclitaxel (14). Following this study, a case report was published in 2015 regarding regression of hydatid cyst lesions in lung cancer treated with cisplatin, docetaxel, carboplatin and pemetrexed (15).

We aimed to share a case of hydatid cyst that regressed after follow-up chemotherapy in our clinic, with the literature.

Case Report

This case report described a 64-year-old male patient with chronic obstructive pulmonary disease (COPD) who was followed for HD at Haydarpaşa Numune Training and Research Hospital, Istanbul, Turkey between 2022 and 2025. The patient did not respond to PAIR, endoscopic retrograde cholangiopancreatography (ERCP), and albendazole treatments. A decision was made to perform surgery; however, during preoperative preparations, lung cancer was diagnosed. Regression of HD was observed following lung cancer treatment.

This study was conducted in accordance with the Helsinki directive. Patient or family consent has been taken.

In his medical history, he had undergone bilateral inguinal hernia surgery 20 years earlier, but he had no other previous operations.

In 2017, he was evaluated at an external center due to abdominal pain. HD was diagnosed as a result of ultrasonography (USG) and magnetic resonance imaging (MRI). PAIR was performed in January 2018. On follow-up USG in July 2018, the lesion size was found to have decreased to 70×80 mm (previously 150×120 mm). After this period, regular follow-up could not be performed for approximately two years due to patient non-compliance.

In 2021, the patient was re-evaluated at an external center with abdominal pain, chills, shivering, and elevated cholestasis enzymes. Due to cholangitis and hyperbilirubinemia, MRI revealed dilatation of the intrahepatic bile ducts and edema in the periportal area and around the intrahepatic bile ducts, and ERCP (endoscopic retrograde cholangiopancreatography) was performed (Laboratory parameters: Alkaline Phosphatase (ALP): 428 u/L, Gamma Glutamyl Transferase (GGT): 1093 u/L, direct bilirubin: 16.74 mg/dL). During ERCP, scolices were observed in the common bile duct, and bile flow was ensured with sphincterotomy.

The patient was subsequently referred to our center. Imaging demonstrated lesions compatible with HD, the largest measuring 65×65 mm in the liver, which were considered to be associated with the bile duct. A thoracic CT scan was performed due to incidental findings of suspicious lung findings. A malignant-appearing lesion was detected in the left lung, and a tru-cut biopsy was performed, revealing squamous cell carcinoma. As the patient had a prior sphincterotomy and his clinical condition was favorable, the multidisciplinary council decided to prioritize lung cancer treatment. After staging, wedge resection was performed for the two foci in the left lung (pathology revealed T3 and T2a tumors with negative surgical margins).

The patient received paclitaxel and carboplatin as adjuvant treatment in April 2022. Although he did not receive andazole and did not undergo surgery afterward, no further cholangitis attacks occurred during 36 months of follow-up, and HD lesions were observed to regress. The patient continued daily life without problems. MRI images were presented in Fig. 1. The patient was followed at 3–6-month intervals. Albendazole was not administered during this period so as not to interfere with oncological treatment.

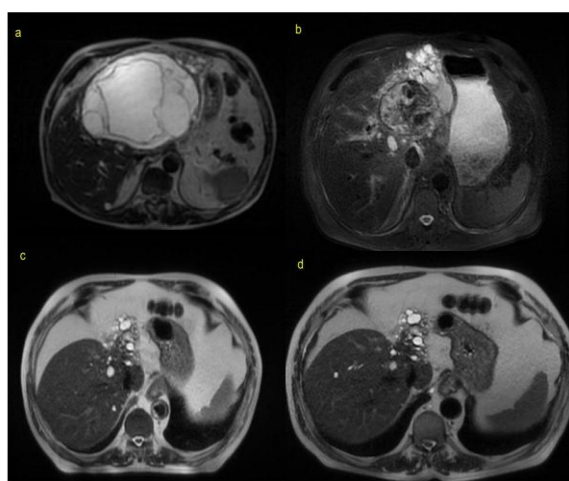


Fig. 1: Changes in Hydatid Cyst Lesions over time (MRI)

- a) Before PAIR treatment (2018)
- b) Before ERCP(2021)
- c) Post-Chemotherapy Control Image (2023)
- d) Post-Chemotherapy Control Image (2024)

Discussion

Treatment of CE was selected according to disease stage and included active surveillance, surgery, PAIR, or medical therapy (5, 7). Especially for patients without clinical complaints, the disease could be controlled with these treatments. However, complications occurred in some patients due to delayed diagnosis or rapid disease progression. Deaths from

anaphylaxis, embolism, and cardiac arrhythmia were reported in autopsy series (16).

Albendazole and its derivatives were used both as alternatives and adjuncts to surgery (13). Reported side effects included hepatotoxicity, renal failure, and neutropenia (17, 18). Experimental studies following advances in nanotechnology demonstrated that nanocapsule formulations of albendazole, mebendazole, and praziquantel were more effective and had fewer side effects than conventional formulations (19). The efficacy of curcumin nanocapsules was demonstrated in a murine experimental study (11).

The severe morbidity and mortality associated with CE stimulated research into new treatments. In addition to existing methods, experimental studies were conducted that offered potential therapeutic hope (14). An experimental study showed dose and time-dependent scolocidal effect of Sanguinari, which appeared promising but required further investigation (10). Another experimental study reported that the harmine derivative H-2-104 might be effective in CS treatment (20).

A case-based report with similar characteristics described regression and progression of HD in a lung cancer patient receiving chemotherapy (15). These findings raised questions regarding the potential role of chemotherapeutic agents in CE treatment. An experimental study conducted in 2014 described the anthelmintic effects of 5-fluorouracil and paclitaxel (14).

Evaluation of the patient for HD facilitated the diagnosis and treatment of lung cancer. In addition, HD regressed following chemotherapy.

Conclusion

Our case was followed for 36 months, during which paclitaxel and carboplatin were administered. No progression of hepatic HD was observed. This effect might have resulted from either drug or their combined action. As

the responsible agent could not be identified, we believe this observation should be supported by further experimental studies.

Acknowledgments

We would like to thank all the staff of Haydarpaşa Numune Training and Research Hospital and Dr. Siyami Ersek Chest, Cardiovascular Surgery Training and Research Hospital, especially Dr. Emre Berat AKÇAY and Dr. Güneş TAYDAŞ, who contributed to the patient.

Competing Interests

There is no conflict of interest among the authors.

References

1. Wen H, Vuitton L, Tuxun T, et al. Echinococcosis: advances in the 21st century. *Clin Microbiol Rev.* 2019;32(2):10.1128/cmr.00075-18.
2. Budke CM, Carabin H, Ndimubanzi PC, et al. A systematic review of the literature on cystic echinococcosis frequency worldwide and its associated clinical manifestations. *Am J Trop Med Hyg.* 2013;88(6):1011-27.
3. Ismail IB, Zaafour EB, Zenaidi H, Rebi S, Zoghalmi A. Acute peritonitis secondary to spontaneous rupture of hepatic hydatid cyst: A case report and literature review. *IDCases.* 2025:e02166.
4. Jedidi M, Mlayeh S, Masmoudi T, Souguir MK, Zemni M. Sudden death due to hydatid cyst: thirty-four medicolegal autopsy cases. *Am J Forensic Med Pathol.* 2014;35(1):29-33.
5. Özdemir Y, Ozer İ, Sürmelioglu A, et al. Risk factors determining bile leakage after multiple liver hydatid cyst surgery. *JOSAM.* 2022;6(3):306-12.
6. Pavlidis ET, Galanis IN, Pavlidis TE. Current considerations for the management of liver echinococcosis. *World J Gastroenterol.* 2025;31(10):103973.
7. Öztürk G, Uzun MA, Özkan ÖF, et al. Turkish HPB Surgery Association consensus report on hepatic cystic echinococcosis (HCE). *Turk J Surg.* 2022;38(2):101-120.
8. Sokouti M, Sadeghi R, Pashazadeh S, et al. A systematic review and meta-analysis on the treatment of liver hydatid cyst using meta-MUMS tool: comparing PAIR and laparoscopic procedures. *Arch Med Sci.* 2019;15(2):284-308.
9. Uzunoglu H, Gül M. A case report of liver and pancreatic echinococcal cysts. *Niger J Clin Pract.* 2022;25(1):114-7.
10. Hassanzadeh E, Khademvatan S, Jafari B, Jafari A, Yousefi E. In vitro and in silico scolicidal effect of sanguinarine on the hydatid cyst protoscoleces. *Plos One.* 2023;18(10):e0290947.
11. Sorouri N, Soleymani N, Sadr S, Rahdar A, Ebrahimzadeh E, Borji H. Investigating the therapeutic effects of curcumin nanocapsules in hydatid cyst-infected mice. *Exp Parasitol.* 2024;267:108860.
12. Sadr S, Lotfalizadeh N, Abbasi AM, et al. Challenges and prospective of enhancing hydatid cyst chemotherapy by nanotechnology and the future of nanobiosensors for diagnosis. *Trop Med Infect Dis.* 2023;8(11):494.
13. Chai JY, Jung BK, Hong SJ. Albendazole and mebendazole as anti-parasitic and anti-cancer agents: an update. *Korean J Parasitol.* 2021;59(3):189-225.
14. Pensel PE, Albani C, Gamboa GU, Benoit JP, Elissondo MC. In vitro effect of 5-fluorouracil and paclitaxel on *Echinococcus granulosus* larvae and cells. *Acta Trop.* 2014;140:1-9.
15. Bangaru SD, Kozarsky PE, Lee DJ, Sica GL, Owonikoko TK. A bystander effect of lung cancer chemotherapy on chronic echinococcal disease. *World J Oncol.* 2015;6(4):416-420.
16. Mahjoub Y, Boussaid M, Mesrati MA, et al. Hydatid disease, an uncommon etiology of death in forensic practice. *Am J Forensic Med Pathol.* 2022;43(2):121-5.
17. Batzlaff CM, Pupaibool J, Sohail MR. Acute renal failure associated with albendazole

- therapy in a patient with trichinosis. *BMJ Case Rep.* 2014;2014:bcr2013200668.
18. Moon SY, Baek YH, Lee SW. Drug induced liver injury by prophylactic administration of albendazole. *Korean J Gastroenterol.* 2019;73(6):360-4.
 19. Soleymani N, Sadr S, Santucci C, Rahdar A, Masala G, Borji H. Evaluation of the In-Vitro Effects of Albendazole, Mebendazole, and Praziquantel Nanocapsules against Protoscolices of Hydatid Cyst. *Pathogens.* 2024;13(9):790.
 20. Gao H, Xu Q, Zhu J, et al. Efficacy and mechanism of action of harmine derivative H-2-104 against *Echinococcus granulosus* infection in mice. *BMC Vet Res.* 2025;21(1):174.