



Tehran University of Medical
Sciences Publication
<http://tums.ac.ir>

Iranian J Parasitol

Open access Journal at
<http://ijpa.tums.ac.ir>



Iranian Society of Parasitology
<http://isp.tums.ac.ir>

Short Communication

Helminth Parasites of Eastern European Hedgehog (*Erinaceus concolor*) in Northern Iran

Mohammad Reza YOUSSEFI¹, Mohammad Taghi RAHIMI², Ali HALAJIAN³, Ali Asghar MOOSAPOUR⁴, Reza NIKZAD⁴, Mohammad NIKZAD⁴, Shahab RAMEZANPOUR⁴,
*Soheil EBRAHIMPOUR⁵

1. Department of Veterinary Parasitology, Islamic Azad University, Babol Branch, Babol, Iran
2. Department of Parasitology, Faculty of Medicine, Mazandaran University of Medical Sciences, Mazandaran, Iran
3. Department of Biodiversity (Zoology), University of Limpopo, Polokwane, South Africa
4. Young Researchers Club, Islamic Azad University, Babol- Branch, Babol, Iran
5. Infectious Diseases and Tropical Medicine Research Center, Babol University of Medical Sciences, Babol, Iran

Received 11 July 2013

Accepted 20 Sep 2013

Keywords

Helminth parasite,
Hedgehog (*Erinaceus concolor*),
Iran

***Correspondence**

Email:

drsoheil1503@yahoo.com

Abstract

Background: Recently there is a high tendency among exotic pet owners for keeping hedgehogs. This mammal can transfer some significant zoonotic pathogens to human. Hence, the present study was conducted for the first time to prepare a list of helminth parasites of hedgehogs (*Erinaceus concolor*) in North of Iran.

Methods: Ten (four males and six females) road killed hedgehogs were collected during April to January 2011 in rural areas of Babol city, Mazandaran province, Iran. All of internal organs were scrutinized for helminth burden. The extracted specimens were fixed and preserved in 70% ethanol and then cleared in Lactophenol solution. Helminth identification was carried out according to available systematic keys.

Results: All the examined hedgehogs (100%) were infected with parasitic helminth as following: two hedgehogs (20%) were infected with *Crenosoma striatum*, four hedgehogs (40%) harbored *Physaloptera clausa*, one (10%) host had *Hymenolepis erinacei* and three (30%) of them were infected with *Nephridiacanthus major*.

Conclusion: This is noteworthy that the current survey is the first report of helminth parasites fauna of Eastern European Hedgehog in Iran. Since this is the first such investigation in our country, more researches are required to perform on unexplored areas of Iran in order to increase our knowledge regarding hedgehog parasitic diseases

Introduction

Hedgehogs are minute mammals of Erinaceidae family. These exotic pets are nocturnal and their body is coated with spiny-like niddles. Recently they are receiving a great attention among pet owners (1, 2). These animals have become increasingly popular as an exotic household pet due to being unique, cute, low and easy maintenance pets. It is estimated that there are more than 40,000 in houses of people in the United States (3, 4). Though hedgehogs traditionally categorized in the now abandoned order of Insectivora, these animals not exclusively insectivores but are nearly considered omnivorous. Hedgehogs feed on insects, snails, frogs, snakes, carrion and mushroom grass roots (5).

This animal can interfere in some zoonotic pathogens such as, *Capillaria aerophila*, *Salmonella* spp. and *Herpes virus*. This rodent can be considered as an appropriate host for a wide variety of parasites, bacteria, viruses and fungi both in medical and veterinary fields (6, 7).

Biogeographically *E. concolor* is considered temperate Eurasian species that is the hedgehog of the well-watered forest, agricultural areas and shrub-land of northwestern and northern Iran through to the Alborz region (8).

To the best of our knowledge, there is no published work on helminthic infection of hedgehogs in Iran though hedgehogs have a cosmopolitan distribution in our country particularly in North of Iran. Thus, the primary objective of the current investigation was to prepare a list of parasitic helminthes of hedgehogs in North of Iran.

Materials and methods

Sampling

An investigation was performed on ten (four males and six females) dead hedgehogs due to road casualties that were hit by cars from April to January 2011 in rural areas of Babol City (36°32' 39" N, 52°40' 44" E) Mazandaran Province, Iran. All of bodies were transferred to Parasitology Laboratory of Islamic Azad

University of Babol for precise examination and identification.

Necropsy

Firstly, individual data of dead hedgehog including site of death, date of collection and gender were recorded precisely. Secondly, at the necropsy process of hedgehog corpses, the abdominal and thoracic cavities were incised and the viscera were removed. The following internal organs were dissected and washed carefully: The lungs, trachea, heart and liver were dissected and rinsed after macroscopic examination for the presence of helminth. Afterwards, the digestive tract (stomach, small intestine and large intestine) were separated and opened up along its entire and frequently rinsed in order to gather the whole contents. The contents of each organ separately were screened by aid of Mesh 70 and in the next step the remnants was sieved and transferred to Petri dishes for more investigation. For the purpose of collecting tiny helminthes which probably are attaching to mucosal layer of the stomach and intestinal tract a stereomicroscope was used (9). All of the isolated specimens from each part of the body were counted, removed, fixed and preserved in 70% ethanol. In the next stage, they were cleared in Lacto phenol and studied in temporary mounts by means of light microscope. The parasites identifications were performed according to available systematic keys including (10-12)

Results

All examined hedgehogs had 100% helminthic infection. From ten examined hedgehogs the following helminthes were obtained: two nematodes, one cestode and one acanthocephalan including *Crenosoma striatum* (*Crenosomatidae*, Fig. 1) (10), *Physaloptera clausa* (*Physalopteridae*, Fig. 2) (10), *Hymenolepis erinacei* (*Hymenolepididae*, Fig. 3) (11) and *Nephridiacanthus major* (*Oligacanthorhynchidae*) (12), respectively.




Fig. 1: Head and tail of *C. striatum* obtained from Hedgehog lung (Photograph by Mohammad Reza Youssefi)




Fig. 2: Head and tail of *Physaloptera clausa* obtained from Hedgehog stomach (Photograph by M.R. Youssefi)

From ten hedgehogs, two (20%) of them were infected with *C. striatum*, four hedgehogs (40%) harbored *Physaloptera clausa*, one (10%) had *Hymenolepis erinacei* and three (30%) of them were infected with *Nephridiacanthus major*.

The localization, prevalence, intensity, abundance, range and median of helminth species in hedgehogs were analyzed and presented in Table 1.

Table 1: Localization and infection rate of extracted helminth from hedgehogs (N: 10)

Parasites	Localisation	Infection %	Hedgehogs ♀	Hedgehogs ♂
<i>C. striatum</i>	Lungs	2(20)	1	1
<i>P. clausa</i>	Stomach	4(40)	2	2
<i>N. major</i>	Small intestine	3(30)	2	1
<i>H. erinacei</i>	Small intestine	1(10)	1	0
Total		10(100)	6	4

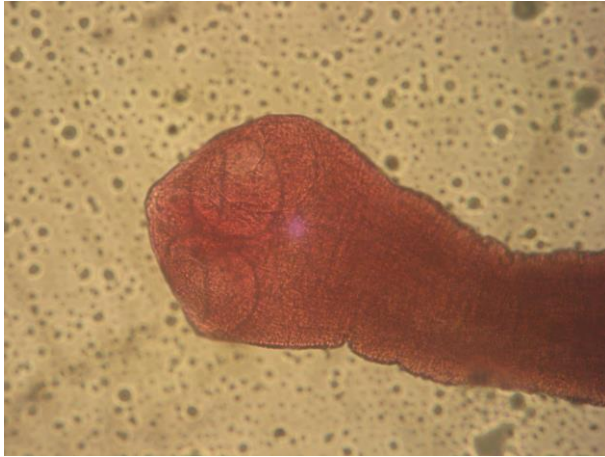

Fig. 3: Scolex of *Hymenolepis erinacei* obtained from Hedgehog small intestine (Photograph by M.R. Youssefi)

Discussion

In the current survey the following helminthes were collected: *C. striatum* from Lung, *P. clausa* in Stomach and *N. major* and *H. erinacei* from Small intestine. The general prevalence of present study noticeably was high (100%) which corresponds to other investigations results (13, 14).

This is the first published wide study on hedgehog helminthes in Iran. However there are two separate studies on two of hedgehogs helminthes in Iran before this study, brief report of *C. striatum* in Urmia (north eastern Iran), although the prevalence (in 10 checked hedgehogs) and the genus and species of hedgehogs are not mentioned (15).

And in the second study, *Nephridiacanthus major* was found in one (of two checked, intensity 2) *Erinaceus concolor* from Mazandaran province and one *Hemiechinus auritus* from Golestan province (intensity 35), acanthocephalan samples were studied morphologically with Light Microscope and Scanning Electron Microscope (for the first time), also histopathology study was done that showed extensive damage of this acanthocephalan to the infected hosts (16). This is worthwhile to clarify that some surveys have proven the major role of

hedgehogs as a reservoir and carrier host in urban, peri-urban and rural environments (17). Poglayen et al. observed *Dicrocoelium dendriticum* and *Haemonchus contortus* in *E. europaeus*. In addition classical ruminant helminthes were reported also from *Atelerix albiventris* (West African Hedgehog) (18, 19). Cirak studied on 18 *E. concolor* (10 females, 8 males) and introduced the following helminth and parasitic burden: *P. clausa* (72.2%), *C. striatum* (55.5%), *A. erinacei* (55.5%), *H. erinacei* (55.5%), *N. major* (50%) and *E. aerophilus* (22.2%) (9). Based on Gaglio investigation on European hedgehogs (*E. europaeus*) by dissection, 91% of studied animals had parasitic helminth infection. Besides, six helminth species were collected including five nematodes (*C. striatum*, *E. aerophilus*, *Capillaria erinacei*, *C. ovoreticulata* and *Capillaria* spp.), one trematode (*Brachylaemus erinacei*) and merely one acanthocephalan (*Oliganthorhynchus erinacei*) (13).

In an elaborate survey on two hedgehogs comprising *Atelerix algirus* and *Paraechinus aethiopicus* in Algeria these helminth species were recognized: One cestodes, *Mathevoatania erinacei*, eight species of nematodes: *Aonchotheca erinacei* in the lumen, spirurids in the intestine, *C. striatum* in the lungs, *Gongylonema mucronatum* (in oesophagus, *P. clausa* in the stomach, *Physaloptera* sp. larvae in the mesentery, *Pterygodermatites plagiostoma* in the stomach, *Spirura rytipleurites seurati* in the intestine; and one acanthocephalan, *Moniliformis moniliformis* in the lumen. The most prevalent species both in *A. algirus* and *P. aethiopicus* was *P. clausa* 64.0% and 64.7%, respectively (14).

As a matter of fact, hedgehogs are primarily insectivores. However, they have a flexible diet, feed on a variety of vertebrate, invertebrate animals as well as carrion and plant matter when accessible. Therefore, they have an immense potential ability about transferring causative agents of diseases owing to having a wide variety of food choices. Nowadays pets have a significant role in societies throughout the world. They are considered as an important companion in many households, contributing in activities such as physical, emo-

tional and social development of children and the well-being of their owners, particularly in the elderly individuals. Despite of this fact that pets offer noticeable benefits, potential treats are associated with pet ownership should not be neglected. Exotic animals are remarkably being invited into homes as pets. Nonetheless, neither pet owners nor veterinary healthcare providers are enough knowledgeable concerning the potential of many of these animals to transfer zoonotic diseases (20).

The following zoonotic helminth parasites were recorded from hedgehog: *Capillaria hepatica* from Switzerland (21), *Moniliformis moniliformis* and *Mathevotaenia* from Algeria (22).

Conclusion

Considering aforementioned facts, it is crystal clear that two major groups including pet owners and veterinary surgeons are more at the risk of zoonose diseases owing to close contact with exotic animals. Control and prevention of zoonotic diseases is associated with breaking the cycle of transmission, and there is no shadow of doubt that education is the major key to control (20). Thus, further precise helminthological investigations are required due to noticeable unexplored area of our country in order to ascend our knowledge concerning helminthic parasites of hedgehogs and probable zoonoses and veterinary diseases.

Acknowledgment

The excellent technical assistance of Department of Veterinary Parasitology, Islamic Azad University, Babol Branch is gratefully acknowledged. The authors declare that there is no conflict of interest.

References

1. Hoefler HL. Hedgehogs. Vet Clin North Am Small Anim Pract. 1994; 24:113–1120.
2. Reiter C, Gould GC. Thirteen Ways of Looking at a Hedgehog. Natural History, Jul–Aug 1998.
3. Woodward D, Khakhria R, Johnson W. Human salmonellosis associated with exotic pets. J Clin Microbiol. 1997; 35: 2786– 2790.
4. Youssefi MR, Rahimi MT, Hosseini SM, Darvishi MM. First Report of *Rhhipicephalus turanicus* from Hedgehog (*Erinaceus concolor*) in North of Iran. World J Zoo. 2011; 6 (4): 401-403.
5. Hutterer R. Order Erinaceomorpha. In Wilson, D. E.; Reeder, D. M. Mammal Species of the World. 3rd ed. Johns Hopkins University Press. 2005; 212–217.
6. Carthy Mc , Moore TA. Emerging helminth zoonoses. Int J Parasitol. 2000. 30: 1351-1360.
7. Riley PY, Chomel BB. Hedgehog zoonoses. Emerg. Infect. Dis. 2005; 11: 1-5.
8. Available at: <http://www.iranicaonline.org>
9. Cirak, VY, Senlik B, Aydogdu A, Selver M, Akyol V. Helminth parasites found in hedgehogs (*Erinaceus concolor*) from Turkey. Prev Vet Med. 2010; 97: 64–66.
10. Yamaguti S. Systema Helminthum: The Nematodes of Vertebrates, Vol. III. Interscience Publishers, New York/London. 1961.
11. Yamaguti S. Systema Helminthum: The Cestodes of Vertebrates, Vol. II. Interscience Publishers, New York/ London. 1959.
12. Yamaguti S. Systema Helminthum: Acanthocephala, vol. V. Interscience Publishers, New York/ London. 1963.
13. Gaglio G, Allen S, Bowden L, Bryant M, Morgan ER. Parasites of European hedgehogs (*Erinaceus europaeus*) in Britain: epidemiological study and coprological test evaluation. Eur J Wildl Res. 2010; 56 (6) 839-844.
14. Khaldi M, Torres J, Samsó B, Jordi Miquel Biche M, Benyettou M, Barech G, Benelkadi HA, Ribas A. Endoparasites (Helminths and Coccidians) in the Hedgehogs *Aterix algirus*- and *Paraechinus aethiopicus* from Algeria. Afr Zool. 2012; 47(1):48-54.
15. Naem, S, Farshid, AA, Tavakkoli M, Ali Mohammadi S. Study on the infection of hedgehogs lungs to *Crenosoma striatum* and pathological changes, 17th Iranian Veterinary Congress, Tehran, April 28-30, 2012, VC-636, P. 651.(In Persian).
16. Heckmann RA, Amin OM, Halajian A, El-Naggar AM. The morphology and histo-

- pathology of *Nephridiacanthus major* (Acanthocephala: Oligacanthorhynchidae) from hedgehogs in Iran. Paras Res. 2012.
17. Visser M, Rehbein S, Wiedemann C. Species of flea (Siphonaptera) infesting pets and hedgehogs in Germany. J Vet Med B. 2001; 48: 197–202.
 18. Poglayen G, Giannetto S, Scala A, Garipp G, Capelli G, Scaravelli D, Brianti E, Reeve NJ. Helminths found in hedgehogs (*Erinaceus europaeus*) in three areas of Italy. Vet Rec. 2003; 152, 22–24.
 19. Kaikabo AA, Kalshingi HA, Saddiq MD, Muazu A, Gashua IB, Suleiman AB. Research Note 1: detection of helminth parasites of ruminants in hedgehog *Atelerix albivetrrix*. Niger J Parasitol. 2007; 28, 129–130.
 20. Robertson ID, Irwin PJ, Lymbery AJ, Thompson RC. The role of companion animals in the emergence of parasitic zoonoses. Int J Parasitol. 2000; 30: 1369–1377.
 21. Brander P, Denzler T, Henzi M. Capillaria hepatica in a dog and a hedgehog. Schweiz Arch Tierheilkd. 1990; 132 (7):365-70.
 22. Khaldi M, Torres J, Samsó B, Miquel J, Biche M, Benyettou M, Barech G, Benelkadi HA, Ribas A. Endoparasites (helminths and coccidians) in the hedgehogs *Atelerix algiru* and *Paraechinus aethiopicus* from Algeria. Afr Zool. 2012; 47: 49-53.