



Tehran University of Medical
Sciences Publication
<http://tums.ac.ir>

Iranian J Parasitol

Open access Journal at
<http://ijpa.tums.ac.ir>



Iranian Society of Parasitology
<http://isp.tums.ac.ir>

Original Article

Isolation, Identification, and Pathogenicity of *Neospora caninum* China Yanbian strain

*Li-jun JIA, Shou-fa ZHANG, Ming-ming LIU, Nian-chao QIAN, Huan-ping GUO

Laboratory of Veterinary Microbiology, Department of Veterinary Medicine, Yanbian University, Yanji, Jilin, China

<p>Received 21 Apr 2014 Accepted 12 Jul 2014</p>	<p>Abstract Background: The aim of the study was to provide a point of reference to study the <i>Neospora caninum</i> infections in China. Methods: Genome DNA was extracted from the brains of aborted fetuses and specific PCR was performed with <i>N. caninum</i> Nc5-targeted specific primers. Fetal bovine brain tissues were homogenized and continuously cultured in Vero cells with double antibodies. The medium was replaced at 2-d intervals and the state of cells was observed. Results: A 608 bp Nc5 gene band was detected by PCR amplification. After sequencing, the sequence of the sample shared 99.5% homology with GenBank (AF061249). Brain homogenates were continuously cultured in Vero cells for 34 d and <i>N. caninum</i> was found. The results of IFAT and Nc5 gene-based PCR detection were <i>N. caninum</i>-positive, and the parasite was tentatively named <i>N. caninum</i> China Yanbian strain. BABL/c mice were inoculated with the separated parasites and showed clinical symptoms of ataxia and limb paralysis after 12 d. Only 3 mice survived. The blood of dying mice and the hearts, livers, spleens, lungs, kidneys, and brains of dead mice were collected aseptically. The Nc5 gene-based PCR showed that <i>N. caninum</i> may exist in brains, livers, and spleen. Based on immunohistochemical observations, we showed that <i>N. caninum</i> tachyzoites existed in the brains and livers. Conclusion: We have successfully isolated bovine-specific <i>N. caninum</i> strain from brain tissues of aborted cattle in the China Yanbian region. This isolated strain has a strong infectious ability towards BABL/c mice.</p>
<p>Keywords: <i>Neospora caninum</i>, Bovine, China, Isolation</p>	
<p>*Correspondence Email: lijunjia1015@sohu.com</p>	

Introduction

Neosporosis, caused by *Neospora caninum*, is a protozoan disease of dogs, cattle, sheep, and other mammals. Neosporosis mainly causes abortions in dams, fetal death, neonatal fetal movement disorders, and nervous system diseases (1, 2). In 1984, an unidentified parasite of the domestic dog was first recognized in cases of encephalomyelitis (brain and spinal disease) and myositis (muscular disease) in Norway, resulting in paralysis in pups and early death; the parasite was morphologically and developmentally similar to *T. gondii* (3). Dubey et al. (4) first isolated the parasites from the bodies of paraplegic dogs and named the parasites *N. caninum*, which was recognized as a new species in 1988. *N. caninum* is an obligate, intracellular, coccidian, protozoan parasite of the phylum Apicomplexa, and Sporozoa, Neosporidia, and Neospora genera. The final host of *N. caninum* is the dog, and a variety of mammals may serve as intermediate hosts, involving the central nervous system, brain, liver, muscle, and other visceral tissues (5). Neosporosis is a cosmopolitan disease, and > 30 countries, including the United Kingdom, the United States, Australia, New Zealand, and South Korea, have reported cases; infection rates range from 10%-40% (highest, 82%) (6-10). Neosporosis had been reported in > 10 provinces, municipalities, and autonomous regions, including Beijing, Qinghai, Xinjiang, Hebei, Jilin, and Heilongjiang of China, causing the most serious harm to cattle, with the highest infection rate of 26.7%; nearly 40% of abortions in cattle are caused by *N. caninum* infections (11-15). With the development of the cattle industry and frequent trading of cattle, Neosporosis has gradually expanded in China, and become one of the important diseases posing a serious threat to the healthy development of the cattle industry (16).

N. caninum can be maintained in African green monkey kidney (Vero) cells and bovine kidney (bk) cells. Diseased and homogenized tissues were acquired from infected animals

and inoculated subcutaneously into mice, rats, gerbils, dogs, cats, and rabbits. The inoculum dose varies according to animal species (17). The central nervous system or visceral tissues were collected for specificity tests and subculture. In the current study, isolation of *N. caninum* from aborted bovine fetal brain tissues by culture in vitro and animal inoculation using IFA, PCR, and other methods was used to identify the parasite.

Materials and Methods

Parasites and Reagents

N. caninum standard strain Nc-1, *Toxoplasma gondii* standard strain RH and African green monkey kidney cell line Vero were contributed by Professor Xue-nan Xuan of the National Research Center for Protozoan Diseases, Obihiro University of Agriculture and Veterinary Medicine. Mouse anti-*N. caninum* sera and mouse anti-*T. gondii* sera were prepared and stored by the Department of Veterinary Medicine of Yanbian University. A Blood DNA Extraction kit, Organization DNA Extraction kit, Agarose Gel DNA Extraction kit, DNA markers, Ex Taq, pMD-18T simple vector, and fluorescent labeled anti-mouse IgG were purchased from Takara Biotechnology (Dalian, China). A Histostain-Plus IHC Kit (mouse primary) was purchased from Neobioscience (Shenzhen, China). DMEM was produced by Life Technologies (Grand Island, New York, USA); Fetal bovine serum was produced from Gibco (Grand Island, New York, USA), and it was inactivated at 56°C for 30 min, then stored at -20 °C.

Test samples and experimental animals

Aborted bovine fetuses (China Yanbian cattle farm, Hunchun, China); ten 6-week-old SPF BALB/c mice (5 males and 5 females) were purchased from the Experimental Animal Center of Jilin University, China and raised in the

IVC system (EHRET GmbH, Mahlberg, Germany).

Nc5 gene-based PCR detection of aborted bovine fetal brain tissue

DNA was extracted from the brains of aborted fetuses using the Organization DNA Extraction kit with *N. caninum* standard strain Nc-1 and *T. gondii* standard strain RH as control, Specific PCR was performed with P1/P2 primers to amplify gene Nc5 of *N. caninum* (AF061249). Primer sequences were as follows:

P1:5'-CGGGATCCGCCGCCAGTCGTTT-AGCAGTTGGGGTGTTC-3'; and P2:5'-CGGAA-TTCCCTGGGAATGGTCAGTGTCCG-3'.

The reaction volume was 20 μ L, and the PCR program was as follow: pre-denaturation at 94 °C for 5 min; denaturation at 94 °C for 45 s; annealing at 56 °C for 1 min; and extension at 72 °C for 1 min for 35 cycles and 72 °C for 10 min. The PCR product was visualized on 10 g/L agarose gel electrophoresis, then the PCR product was extracted using an Agarose Gel DNA Extraction kit and cloned into a pMD18-T simple vector. The positive clone was sequenced by Sangon Biotech (Shanghai, China).

In vitro culture of N. caninum in aborted bovine fetal brain tissue

Five grams of aborted fetal brains were obtained with aseptic manipulation and added to 100 U/mL of penicillin-streptomycin (Solarbio, Beijing, China), then repeat filtered 5 times through an 18-G needle. Two hundred microliters of brain homogenate were harvested and inoculated into 4 portions of monolayer Vero cells, then cultured at 37 °C in 5% CO₂ and saturated humidity. The culture medium was changed 12 h post inoculation, then replaced every 2 days. An inverted microscope was used to observe the conditions of Sertoli cells daily.

IFAT and PCR identification

Vero cells infected with *N. caninum* were cultured in 12-well plates, dried naturally, and fixed with cold acetone for 10 min. Mouse anti-*N. caninum*-positive sera were added onto the fixed cells and incubated for 1 h at 37 °C, followed by thrice-washing with phosphate-buffered saline (PBS). Then, fluorescein isothiocyanate (FITC)-labeled anti-mouse IgG was applied to the cells and incubated for 1 h at 37 °C, followed by thrice-washing with PBS. The cells were observed and photographed under a fluorescence microscope. Infected Vero cell DNA genomes were extracted, the PCR method (as in section 1.3) was performed and the amplification products were sequenced.

Animal inoculation

N. caninum cultured in Vero cells was filtered with a 27-G needle 5 times, then through a 5.0 μ m filter and centrifuged at 2 000 r/min for 10 min. *N. caninum* were collected and the number was counted. Ten BALB/c mice (Experimental Animal Center of Jilin University, Changchun, China) were intraperitoneally inoculated using the collected parasites. Each mouse was inoculated with 10⁵ parasites. The inoculated BALB/c mice were housed in the IVC system (EHRET GmbH, Mahlberg, Germany). Clinical symptoms and diseases were observed daily.

PCR test on N. caninum isolated from BALB/c mice

First, dying mouse blood and *N. caninum* philic organs (hearts, livers, spleens, lungs, kidneys, and brains) of dead mice were collected. Second, template DNA was extracted from the prepared materials in the first step using a Blood Genome DNA Extraction kit (TaKaRa Bio, Dalian, China) and a Tissue DNA Extraction kit (TaKaRa Bio). Third, a PCR test was applied to the template DNA and according to Method 1.3 for targeting the Nc5 gene.

Immunohistochemical observation

The organs of all BABL/c mice were collected, including the hearts, livers, spleens, lungs, kidneys, and brains through paraffin embedding and slicing. Then, an immunohistochemical test was used on the preparations and rat resistance *N. caninum*-positive serum was the first antibody using a mouse Immunohistochemical Kit (NeoBioscience Technology Company Limited, Shenzhen, China) to determine the distribution of *Neospora*.

Results

PCR test targeting the Nc5 gene in abortus cattle

The PCR test showed targeting the Nc5 gene banding in templates of *N. caninum* Nc-1 standard strain and abortus cattle brain tissues, whereas, no relevant PCR results were detected from *T. gondii* RH standard strain and negative control (Fig. 1). Blasting results suggest there was 99.5% homology between abortus cattle brain-extracted DNA and the AF061249 (GenBank) gene sequence, which indicates a great existent possibility of *N. caninum* in the abortus cattle.

IFAT combining PCR Identification

N. caninum was detected in all four pieces of Vero cells after inoculating abortus cattle tissue homogenates and consecutive culturing for 34 d (Fig. 2). IFAT was performed in the experimental and control groups. In the experimental group, the inoculated cell fluid, rat resistance *N. caninum*-positive serum (first antibody), as well as fluorescein beaoned resistance rat IgG (second antibody) were included in the IFAT. In the control group, the elements targeted *T. gondii*.

Green fluorescence was observed in the experimental group in contrast to no fluorescence in the control group, which confirms that suspected infections can be identified by rat resistance *N. caninum*-positive serum and produce a specific immunity response (Fig. 3). With resp

ect to the PCR test, sequencing and blasting was performed for further identification. PCR product targets the Nc5 gene and there was 99.5% homology between abortus cattle brain-extracted DNA and the AF061249 (GenBank) gene sequence, which is consistent with results from abortus cattle brain tissue and confirming *N. caninum*. Thus, we temporarily named the parasite "bovine-specific *N. caninum* strain from the China Yanbian region."

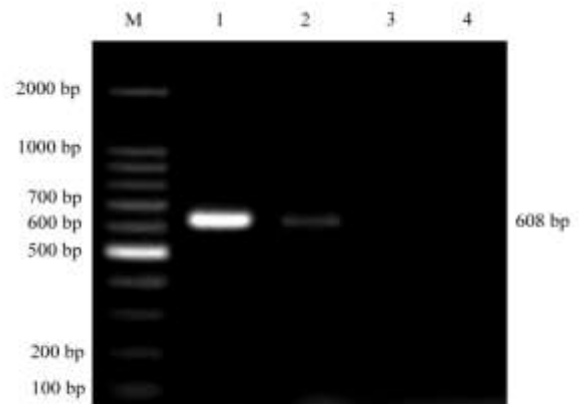


Fig. 1: Nc5 gene-based PCR detection of aborted fetal bovine brain tissue

M: DNA marker DL2 000; 1: Nc-1 standard strains of DNA; 2: aborted fetal bovine brain tissue DNA; 3: *Toxoplasma gondii* RH strain DNA; 4: negative control

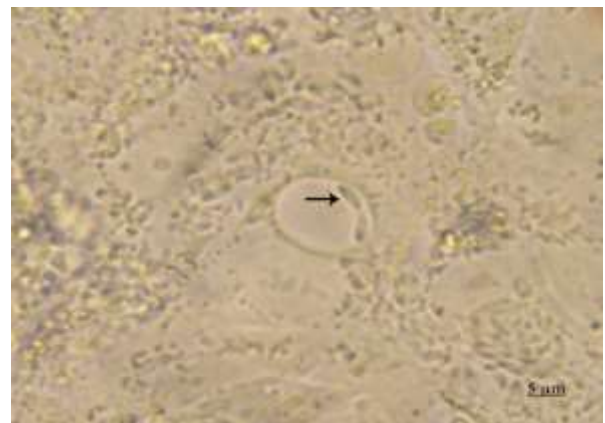


Fig. 2: *N. caninum* in Vero cells continuously cultured for 34 d (800X)

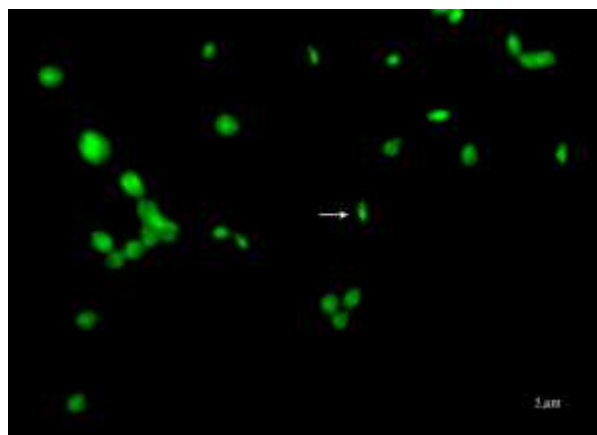


Fig. 3: IFAT identification of *N. caninum* cultured in Vero cells (800X)

In vivo test

"Bovine-specific *N. caninum* strain from the China Yanbian region" was inoculated into BALB/c mice. Beginning on the 5th day after inoculation, the receptors were depressed, the fur was inverted, the appetite was lost and ataxia, quadriplegia were developed; and the mice began to die on the 12th d and 10 BALB/c mice only 3 mice survived to the 20th d. There were positive results from the brains, livers, and spleens, and negative findings from

other tested organs and blood of dying mice through PCR testing (Fig. 4), which indicates *N. caninum* has invaded into receptor-positive resulting organs and was responsible for all the developing clinical symptoms.

Immunohistochemical test identification

Paraffin embedding and slicing towards organs (heart, liver, spleen, lung, kidney, brain, etc.) were prepared from dead BALB/c mice. Rat resistance *N. caninum* serum was the first antibody to be applied in immunohistochemical testing. Immunohistochemistry staining and microscopy inspection were operated, we observed brain tissue cells aggregated, focal inflammation, liver cells degeneration, Local inflammatory cells infiltration, and dark brown stained *N. caninum* tachyzoites were observed in the brain and liver tissue sections (Fig. 5A and B). Inflammatory changes and localized necrosis existed in the spleen, lung, kidney, heart, etc, but caninum tachyzoites weren't found. Which confirms that *N. caninum* invades the brain and liver tissues of BALB/c mice.

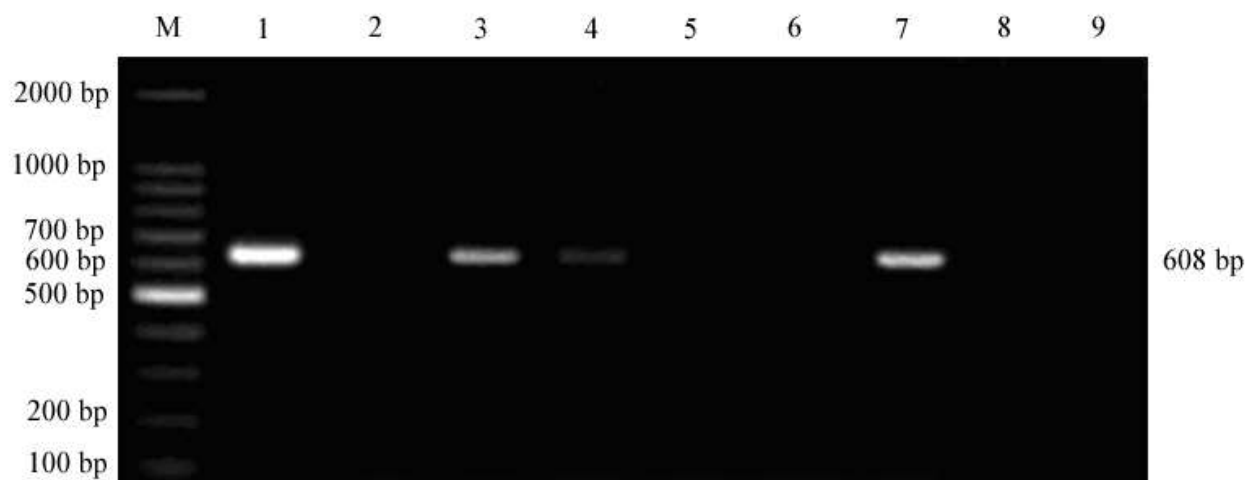


Fig. 4: Nc5 gene-based PCR detection of organs and blood of *N. caninum* inoculated BALB/c mice
M: Marker DL2 000; 1: Nc-1 standard strain; 2: heart; 3: liver; 4: spleen; 5: lung; 6: kidney; 7: brain; 8: blood; 9: negative control

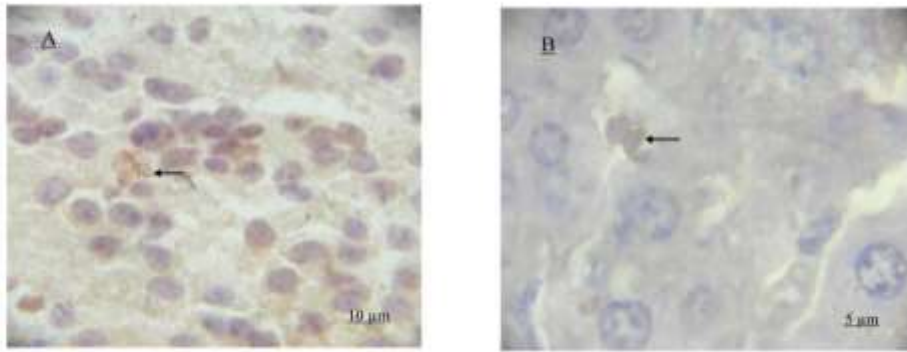


Fig. 5: Immunohistochemical staining of brain and liver tissue slices of dying of BALB/c mice
A: brain (←tachyzoites); B: liver (←tachyzoites)

Discussion

In the current study, the DNA of Nc-1 standard strain of *N. caninum* and the RH standard strain of *T. gondii* were used as the control and abortus fetal calf brain tissue DNA was identified using *N. caninum* Nc5 gene-specific primer. The 608 bp Nc5 gene fragment has been amplified from *N. caninum*; however, the *T. gondii* gene fragment was not amplified, so we could not exclude the possibility of *T. gondii* infection. The homology between the amplified Nc5 gene and the NcSRS2 (AF061249) nucleotide sequence in GenBank was 99.5%, which confirmed the abortus fetal calf was caused by *N. caninum*. *N. caninum* and *T. gondii* are intracellular parasitic protozoa with close genetic relationships. *N. caninum* and *T. gondii* have similar morphologic structures, molecular biology characteristics, clinical symptoms, and pathological changes, so *N. caninum* was initially mistaken for *T. gondii* (1, 18, 19). When canine *N. caninum* was identified, the possibility of *T. gondii* was excluded. The Nc5 gene, as an important function marker gene of *N. caninum*, has low homology with the *T. gondii* isotopic gene, which can be used to distinguish between *N. caninum* and *T. gondii* (20-22).

Davison et al. (1) inoculated 10 g of fresh stillborn calve brain tissues digested with 0.5% trypsin to 6 parts Vero cells maintained at 37 °C in RPMI-1640 culture medium containing 5%

CO₂ in 95% air. 29 d post-inoculation, typical *N. caninum* tachyzoites were observed in culture medium for the first time. Yamane et al. (2) collected 16 aborted fetuses and suspected neosporosis calf tissue samples, then inoculated the parasites in bovine pulmonary artery endothelial cells and monkey kidney cells. 49 d post-inoculation, *N. caninum* tachyzoites were observed. In the current study, aborted fetal bovine brain tissue homogenates were inoculated in Vero cells. The suspected parasites were observed after culture for 34 d and were identified by PCR amplifying, IFAT and Nc5 genes sequence analysis. The results confirmed that the parasite was *N. caninum* and thus named *N. caninum* (China Yanbian strain).

Lindsay et al. (23) reported that *N. caninum* is a perineural tissue parasite, with cysts existing in the nervous system far more likely than other organizations. However, Peters et al. (24) reported that the muscle can be observed in cysts. In the current study, the *N. caninum* Nc5 gene fragment was detected in the brains, livers, spleens, and brains of aborted fetuses and inoculated mice. Moreover, *N. caninum* tachyzoites were observed in brain and liver tissue sections by immunohistochemistry, while other organizations were not because during *N. caninum* transitional process in animals has different parasitic tissues (25, 26).

Sharifdini et al. (27) reported, *N. caninum* and *L. infantum* co-infection in domestic dogs is prevalent in the CVL endemic areas of

northwestern Iran and the infection by *L. infantum* seems to enhance susceptibility to *N. caninum* infection. In the survey in Goat farms in Slovakia, Čobádiová et al. (28) found cases coinfection of *T. gondii* and *N. caninum*. In this study, caninum were isolated from aborted fetal bovine brain tissue by Vero cells, no other pathogen was found, and whether abortion cow infections of other pathogens needs further validation.

Okeoma et al. (29) reported that *N. caninum* DNA appears in naturally infected cattle blood leukocytes, which results in parasitaemia as *N. caninum* spreads in the host systemically. In experimental natural infections, parasitaemia in experimental animals is difficult to detect due to the shorter test time and the changes in experimental conditions (30, 31). Chong et al. (32) detected *N. caninum* DNA in BALB/c mouse blood-infected tachyzoites. In this research, *N. caninum* DNA was not detected in moribund BALB/c mouse blood after insect attack, which may be related to the above factors.

Conclusion

Neospora caninum Yanbian strains of China in cattle was successfully isolated from aborted fetal bovine brain tissue, and shown to have strong pathogenicity in BALB/c mice.

Acknowledgments

The project was supported by the National Natural Science Foundation (31160501; 3136-0605) in China and Foundation (201201076; 20140204078NY) in Jilin Science and Technology Department. The authors declare that there is no conflict of interests.

References

1. Davison HC, Trees AJ, Guy F, Otter A, Holt JJ, Simpson VR, Jeffrey M. Isolation of bovine *Neospora* in Britain. *Vet Rec.* 1997; 141:607.
2. Yamane I, Kokuho T, Shimura K, Eto M, Shibahara T, Haritani M, Ouchi Y, Sverlow K, Conrad PA. In vitro isolation and characterization of a bovine *Neospora* species in Japan. *Rec Vet Sci.* 1997; 63: 77-80.
3. Bjerkås I, Mohn SF, Presthus J. Unidentified cyst-forming sporozoan causing encephalomyelitis and myositis in dogs. *Z Parasitenkd.* 1984; 70:271-274.
4. Dubey JP, Carpenter JL, Speer CA, Topper MJ, Uggla A. Newly recognized fatal protozoan disease of dogs. *J Am Vet Med Assoc.* 1988; 192:1269-1285.
5. Dubey JP. Neosporosis in cattle; biology and economic impact. *J Am Vet Med Assoc.* 1999; 214:1160-1163.
6. Thurmond MC, Hietala SK. Effect of *Neospora caninum* infection on milk production in first-lactation dairy cows. *J Am Vet Med Assoc.* 1997; 210:672-674.
7. Stenlund S, Kindahl H, Magnusson U, Uggla A, Björkman C. Serum antibody profile and reproductive performance during two consecutive pregnancies of cows naturally infected with *Neospora caninum*. *Vet Parasitol.* 1999; 85:227-234.
8. Jenkins M, Baszler T, Björkman C, Schares G, Williams D. Diagnosis and seroepidemiology of *Neospora caninum*-associated bovine abortion. *Int J Parasitol.* 2002; 32:631-636.
9. Cramer G, Kelton D, Duffield TF, Hobson JC, Lissemore K, Hietala SK, Peregrine AS. *Neospora caninum* serostatus and culling of Holstein cattle. *J Am Vet Med Assoc.* 2002; 221:1165-1168.
10. Cañón-Franco WA, Bergamaschi DP, Labruna MB, Camargo LM, Souza SL, Silva JC, Pinter A, Dubey JP, Gennari SM. Prevalence of antibodies to *Neospora caninum* in dogs from Amazon, Brazil. *Vet Parasitol.* 2003; 115:71-74.
11. Chao W, Ma L, Li W, Zhang Z, Li D, Han W. Serological investigation of *Neospora caninum* infection in dairy cows in Geermu county of Qinghai province. *Chinese J Vety Sci Technol.* 2005; 35:1012-1014.
12. Liu Q, Li B, Qi C, Zhu Y. The first report on the serological test of Neosporosis in dairy cows. *Chinese J Vet Med.* 2003; 39:8-9.
13. Bayin C, Hao J, Wang C. Serologic tests with the recombinant NcSRS1 antigen on the cattle infected with *Neospora caninum* in Xinjiang partial areas. *Chinese J Vet Parasitol.* 2008; 16:10-12.
14. Zhang S, Ding D, Ju Y, Jia L. The comparison of colloidal gold immunochromatography and ELI-

- SA used in the detection of *Neospora caninum* sera antibody. Chinese J Vet Med. 2008; 44:54-55.
15. Wang C, Li Z, Zhai Y, Ni H, Chen A, Chen J, Wang N. Development and preliminary application of indirect ELISA diagnostic method for *Neospora caninum* in dairy cattle. Chinese J Prevent Vet Med. 2009; 31:145-149.
 16. Deng C, Zhang W, Liu Q, Hu D, Yu X, Liu J. Identification of *Neospora caninum* in aborted fetus of dairy cow in China. Chinese Vet Sci. 2007; 37:16-19.
 17. Ding D, Jia L, Tian W, Liang W, Zhang X, Zhang S. Isolation and identification of Jilin strain *Neospora caninum*. Chin Vet Sci. 2009; 29:423-425.
 18. Langoni H, Matteucci G, Medici B, Camossi LG, Richini-Pereira VB, Silva RC. Detection and molecular analysis of *Toxoplasma gondii* and *Neospora caninum* from dogs with neurological disorders. Rev Soc Bras Med Trop. 2012; 45:365-368.
 19. Meerburg BG, De Craeye S, Dierick K, Kijlstra A. *Neospora caninum* and *Toxoplasma gondii* in brain tissue of feral rodents and insectivores caught on farms in the Netherlands. Vet Parasitol. 2012; 184:317-320.
 20. Hughes JM, Williams RH, Morley EK, Cook DA, Terry RS, Murphy RG, Smith JE, Hide G. The prevalence of *Neospora caninum* and co-infection with *Toxoplasma gondii* by PCR analysis in naturally occurring mammal populations. Parasitology. 2006; 132:29-36.
 21. Ghalmi F, China B, Kaidi R, Daube G, Losson B. Detection of *Neospora caninum* in dog organs using real time PCR systems. Vet Parasitol. 2008; 155:161-167.
 22. Truppel JH, Montiani-Ferreira F, Lange RR, Vilani RG, Reifur L, Boerger W, da Costa-Ribeiro MC, Thomaz-Soccol V. Detection of *Neospora caninum* DNA in capybaras and phylogenetic analysis. Parasitol Int. 2010; 59:376-379.
 23. Lindsay DS, Dubey JP, Duncan RB. Confirmation that the dog is a definitive host for *Neospora caninum*. 1999; Vet Parasitol 82:327-333.
 24. Peters M, Lütkefels E, Heckerroth AR, Schares G. Immunohistochemical and ultrastructural evidence for *Neospora caninum* tissue cysts in skeletal muscles of naturally infected dogs and cattle. Int J Parasitol. 2001; 31:1144-1148.
 25. De Marez T, Liddell S, Dubey JP, Jenkins MC, Gasbarre L. Oral infection of calves with *Neospora caninum* oocysts from dogs: humoral and cellular immune responses. Int J Parasitol. 1999; 29:1647-1657.
 26. Pereira-Bueno J, Quintanilla-Gozaló A, Pérez-Pérez V, Espi-Felgueroso A, Alvarez-García G, Collantes-Fernández E, Ortega-Mora LM. Evaluation by different diagnostic techniques of bovine abortion associated with *Neospora caninum* in Spain. Vet Parasitol. 2003; 111: 143-152.
 27. Sharifdini M, Mohebalí M, Keshavarz H, Hosseininejad M, Hajjarian H, Akhoundi B, Foroushani AR, Zarei Z, Charehdar S. *Neospora caninum* and *Leishmania infantum* Co-Infection in Domestic Dogs (*Canis familiaris*) in Meshkin-Shahr District, Northwestern Iran. Iran J Arthropod-Borne Dis, 2011, 5(2): 60–68.
 28. Čobádiová A, Reiterová K, Derdákóvá M, Špilovská S, Turčekóvá L, Hviščová I, Hisira V. *Toxoplasma gondii*, *Neospora caninum* and tick-transmitted bacterium *Anaplasma phagocytophilum* infections in one selected goat farm in Slovakia. Acta Parasitol. 2013, 58(4):541-546.
 29. Okeoma CM, Williamson NB, Pomroy WE, Stowell KM, Gillespie L. The use of PCR to detect *Neospora caninum* DNA in the blood of naturally infected cows. Vet Parasitol. 2004; 122: 307-315.
 30. Maley SW, Buxton D, Rae AG, Wright SE, Schock A, Bartley PM, Esteban-Redondo I, Swales C, Hamilton CM, Sales J, Innes EA. The pathogenesis of neosporosis in pregnant cattle: inoculation at mid-gestation. J Comp Pathol. 2003; 129:186-195.
 31. Macaldowie C, Maley SW, Wright S, Bartley P, Esteban-Redondo I, Buxton D, Innes EA. Placental Pathology associated with fetal death in cattle inoculated with *Neospora caninum* by two different routes in early pregnancy. J Comp Pathol. 2004; 131:142-156.
 32. Deng C, Zhang W, Liu Q, Liu J, Ding J. BALB/c Mouse Model of neosporosis and the development process with infection of *Neospora caninum*. Scientia Agricultura Sinica. 2009; 42:1123-1128.