



Tehran University of Medical
Sciences Publication
<http://tums.ac.ir>

Iran J Parasitol

Open access Journal at
<http://ijpa.tums.ac.ir>



Iranian Society of Parasitology
<http://isp.tums.ac.ir>

Case Report

Ocular Toxocariasis Associated with Blurred Vision and Visual Impairment: Report of Four Cases

*Mohammad Zibaei^{1,2}, Fatemeh Sadat Mahdavi³, Farzaneh Firoozeh⁴, Hamidreza Hasani⁵, Saeed Bahadory⁶

1. Department of Parasitology and Mycology, School of Medicine, Alborz University of Medical Sciences, Karaj, Iran
2. Evidence-Based Phytotherapy and Complementary Medicine Research Center, Alborz University of Medical Sciences, Karaj, Iran
3. Student Research Committee, School of Medicine, Alborz University of Medical Sciences, Karaj, Iran
4. Department of Microbiology, School of Medicine, Alborz University of Medical Sciences, Karaj, Iran
5. Department of Ophthalmology, Madani Medical Center, School of Medicine, Alborz University of Medical Sciences, Karaj, Iran
6. Department of Parasitology, Faculty of Medical Sciences, Tarbiat Modares University, Tehran, Iran

Received 10 Aug 2021
Accepted 14 Nov 2021

Keywords:

Ocular toxocariasis;
Granuloma;
Blurred vision;
Visual impairment;
Serodiagnosis;
Iran

*Correspondence

Email:
zibaeim@sums.ac.ir

Abstract

Ocular toxocariasis in humans is caused by infection with larvae of *Toxocara* species, which are common ascarid roundworms of mammals, kept in close proximity to human. Four cases with a history of contact with dogs and cats and blurred vision and visual impairment over periods of variable duration were examined. We screened patients diagnosed with ocular larva migrans syndrome between March and June 2021 at the Ophthalmology clinics affiliated with Alborz University of Medical Sciences, Karaj, Iran. Detailed demographics, clinical characteristics, and fundus photography were recorded. Anti-*Toxocara* antibodies in the sera and vitreous fluid detected by ELISA. Complete recovery in all four patients was achieved following treatment with oral albendazole. The diagnosis of ocular toxocariasis can be challenging, because both the condition is relatively uncommon and its presentation varies from patient to patient. There are lots of differential diagnoses like retinoblastoma, therefore correct, quick diagnosis, and treatment is very important.

Introduction

Toxocara infection is one of the most commonly reported zoonotic helminth infections in the world with a higher prevalence

in tropical settings and in rural populations. It is caused by the larval stages of the ascarid *Toxocara canis*, the common roundworm of dogs, and by the



larval stages of *T. cati*, the roundworm of cats (1). Accidentally ingestion of *Toxocara* species eggs containing second-stage larvae, due to geophagia, pica, and the consumption of contaminated raw meat or liver, is considered as possible cause of visceral larva migrans (VLM), ocular larva migrans (OLM), neurotoxocariasis (NT), and hidden or covert toxocariasis (CT). The prevalence of toxocariasis is higher in tropical and developing countries due to their lower socio-economic level (2).

Ocular form of toxocariasis or OLM is rare and is commonly caused by a single larva. Ocular lesions may be due to direct damage caused by the parasites or indirect pathology caused by toxic products of parasites and may be due to the immune response to infectious parasitism. Although it can create a significant inflammatory reaction and determinate the patient's vision, a definitive diagnosis and treatment of ocular toxocariasis is challenging since the larvae is hardly identified from the lesions and its clinical presentations can mimic other causes of uveitis. Accurate and quick diagnosis of OLM is necessary to prevent permanent visual damage (3,4).

Diagnosis of ocular toxocariasis is based on a combination of clinical, laboratory and radiological findings. The serodiagnosis of ocular toxocariasis

based on detection of specific anti-*Toxocara* antibodies (IgG) could be used as laboratory evidence of the disease, but the interpretation of the required ELISA results is not simple (5). Serum-*Toxocara* antibodies tested positive in 2 to 18% of an apparently healthy population, suggesting possible past, and self-cured infections (6). Therefore, the detection of anti-*Toxocara* antibodies in the intraocular fluid has been suggested to confirm the diagnosis.

Here, we describe four patients who presented with blurred vision and visual impairment for the variable duration and the lesions were clinically compatible, and the ocular toxocariasis confirmed using ELISA and detection of anti-*Toxocara* immunoglobulin G in the serum and vitreous fluid.

Cases presentation

The purpose of the report was explained to patients and informed consent was obtained from the patients. The diagnostic procedures including ethical aspects were reviewed and approved by the Ethics Committee of Alborz University of Medical Sciences (IR. ABZUMS. REC.1395, 103). We describe the observed clinical features of four patients with ocular toxocariasis (Table 1).

Table 1: Clinical manifestation in the patients with ocular toxocariasis

Cases number	Age/Sex	Occupation	Animal contact	Signs and symptoms	Eosinophils (%)
Case 1	25/F	Collegian	Cat	Chronic granulomatous posterior uveitis, photophobia, chorioretinitis, blurred vision, posterior pole granular	1.6
Case 2	30/M	Carpet seller	Dog/Cat	Acute non-granulomatous posterior uveitis, chorioretinitis, blurred vision	2.3
Case 3	47/F	Housekeeper	Dog	Chronic non-granulomatous pan-uveitis, retinal inflammation, blurred vision, cataract	0.7
Case 4	52/M	Farmer	Dog/Cat	Subacute granulomatous posterior uveitis, blurred vision and eye pain	5.7

F: Female; M: Male

Case 1

A 25-year-old female with blurred vision, photophobia, and chronic granulomatous posterior uveitis admitted to the university affiliated Ophthalmology Clinic (Fig. 1A). An epidemiological interview confirmed a direct contact with kitten. She had a history of general ache and concurrent onset of ocular symptoms the day after eating un-

cooked meat. A clinical diagnosis of ocular toxocariasis was made with a positive history of repeated ingestion of raw liver, regarded as a significant risk factor of *Toxocara* infection, and detection of anti-*T. canis* antibodies in the serum sample and vitreous fluid by ELISA (NovaTec Immunodiagnostica GmbH, Dietzenbach, Germany) and exclusion of other ocular conditions causing exudative macular

lesion (Table 2). A complete blood count showed a leukocyte count of 9700/ μ L with marked eosinophils 1.6% (Table 3). She was started treatment with oral prednisone (30 mg daily for 2 weeks) and

albendazole (200 mg twice for 5 days) according to existing protocols (7). Three months after the first examination, her visual acuity had improved.

Table 2: Evaluation of anti-*Toxocara* antibodies enzyme-linked immunosorbent assays in the patients

<i>Cases</i>	<i>First result (OD)¹</i>		<i>Repeat of the test (OD)</i>	
	Serum	Vitreous fluid	Serum	Vitreous fluid
Case 1	34	41.2	33	41.4
Case 2	18.1	21.4	18.6	20.8
Case 3	27.5	35.3	32.2	33.3
Case 4	44.6	41.0	52.4	55.0

OD (Optical density): Compared to negative and positive controls, samples with absorbance ≤ 9 were considered negative while absorbance ≥ 11 was considered positive, between 9.1–10.9 as equivocal (manufacture's recommendations)

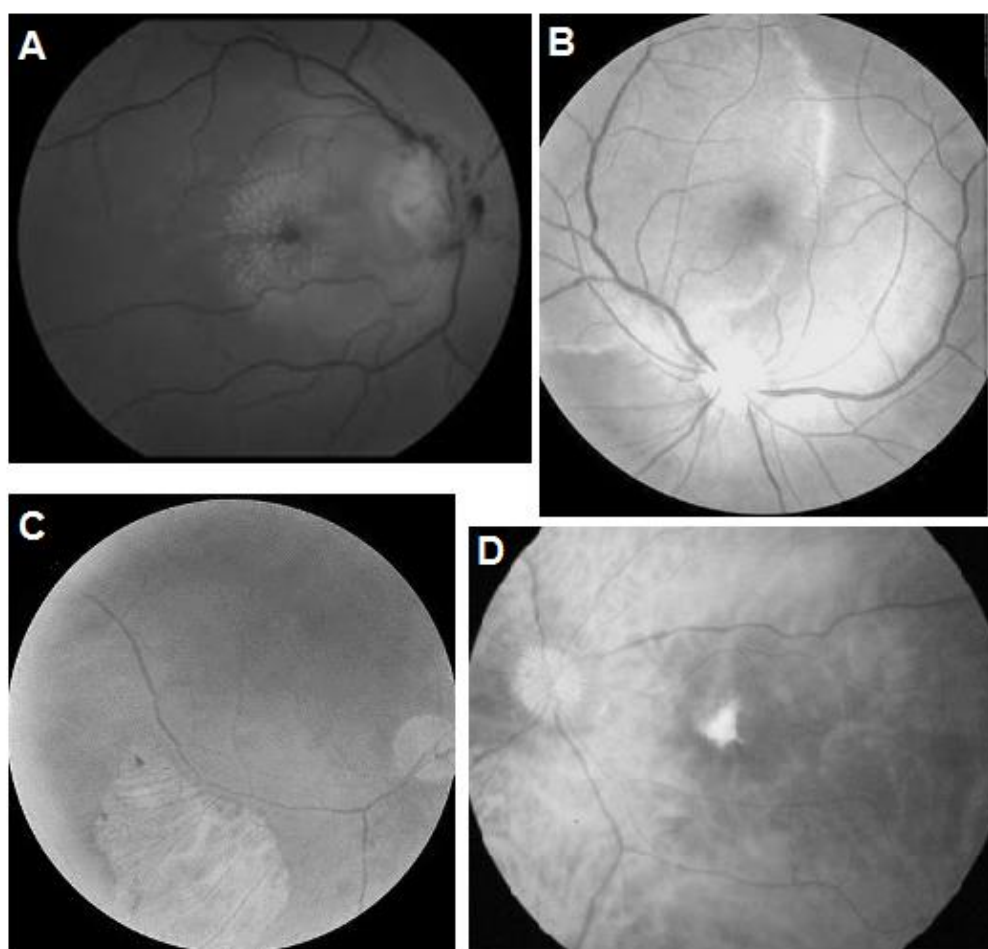


Fig. 1: The fundus photographs of the patients shows chorioretinitis and uveitis. (A) Case 1: Chronic granulomatous posterior uveitis with photophobia, chorioretinitis, blurred vision, and posterior pole granular was noted. (B) Case 2: An acute non-granulomatous posterior and intermediate uveitis and chorioretinitis was observed. (C) Case 3: Chronic non-granulomatous panovitis with retinal inflammation. (D) Case 4: View of a white mass in the temporal lower retina

Case 2

A 30-year-old male with vision impairment was referred from ophthalmology clinic to the parasitology department. He had an occupation as carpet seller and a history of contact with pet animals. He was complaining of blurred vision and ophthalmological consultation showed an acute non-granulomatous posterior and intermediate uveitis and chorioretinitis in the right eye. The fundus photography of the eye was also showed a vitritis (Fig. 1B). The anti-*Toxocara* IgG was considered positive in the serum sample tested using ELISA, when the value was higher than 11 U by the manufacturer. On the other hand, the anti-*Toxocara* antibodies were also positive in the vitreous fluid, which confirmed the diagnosis of ocular toxocariasis (Table 2). A blood test showed a white blood cell count of $12.3 \times 10^3/\mu\text{L}$ and an eosinophil rate of 2.3% (Table 3). The patient was treated with oral albendazole 15 mg/kg/day for 7 days. Prednisone at an oral dosage 0.5 mg per kg daily was co-administered for the first week of therapy to prevent allergic reactions due to accelerated larval lysis. A rapid improvement of both laboratory and symptoms findings were observed and no side effects were complained. Anti-*Toxocara* antibodies titer against the excretory-secretory antigens became much reduction in the three six months after starting treatment.

Case 3

A 47-year-old housewife female, referred to the ophthalmology department, had symptoms of blurred vision, and eye discomfort with complaints of reduced visual acuity of six months' duration. This patient sought medical advice because of blurred vision in the left eyes. After a careful evaluation of her eyes, ophthalmic photographs were showed chronic non-granulomatous panuveitis, retinal inflammation and cataract (Fig. 1C). There was a history of contact with puppies. Serological findings have shown positive-ELISA for the vitreous fluid and serum anti-*Toxocara* IgG, and blood laboratory tests disclosed leukocytosis without eosinophilia (0.7 percent) (Tables 2 and 3). Albendazole (200 mg/twice/15 days) and oral steroids (methylprednisone, 64 mg) have both been received as treatment options. There was initial

improvement of the vitritis with significant vitreous debris.

Case 4

A 52-year-old male patient visited an ophthalmologist because of visual field defect in the right eye. He was referred to the parasitology laboratory. The patient had bilateral cataract and bullous retinal detachment and fundoscopic examination of the right eye showed a white mass in the temporal lower peripheral retina (Fig. 1D). Testing showed strongly positive serology for toxocariasis detected by immunoenzymatic assay (Table 2) and other laboratory abnormalities (Table 3). Empirical antiparasitic therapy for ocular toxocariasis was started (oral albendazole 400 mg/daily and oral prednisone 30 mg for 10 days) as well retinal detachment was treated by retinal cryocoagulation, scleral buckling, and subretinal fluid drainage.

Discussion

Ocular larva migrans, is also known as ocular toxocariasis, is a neglected zoonotic parasitic infection in mostly underprivileged communities in non-industrialized as well industrialized countries (8).

Ocular toxocariasis manifesting as granulomatous uveitis can be classified into four subtypes: peripheral granuloma, posterior pole granuloma, chronic endophthalmitis, and combined type (9).

It is an eye disease caused by larvae mostly from animal nematodes, *Toxocara* species. This infection has a worldwide distribution and the annual incidence of ocular toxocariasis in different parts of the world ranges between 17 and 52 per 100,000 persons, and the prevalence ranges between 58 and 115 per 100,000 people (3). The seroepidemiological studies in Iran report a *Toxocara* seroprevalence rate of 25.6% amongst the children and up to 5.2% amongst people at risk (2,10).

In our presented cases, the clinical presentation characterized by granulomatous anterior, posterior uveitis, photophobia, chorioretinitis, posterior pole granular, vitritis, bullous retinal detachment, reduced visual acuity, bilateral cataract, and typically blurred vision. In the patients, increase in eosinophilia was not observed.

Table 3: The results of patients' paraclinical tests

<i>Indicator</i>	<i>The patient's values</i>				<i>Normal value</i>
	Case 1	Case 2	Case 3	Case 4	
White blood count, mm ³ /μL	10.9	12.3	16.2	13.7	4-11
Hemoglobin, g/dL	13.8	15.2	14.7	14.2	13.5-17.7
Platelets, per mm ³ /μL	234	315	410	286	150-450
Eosinophil, cell/μL (%)	1.6	2.3	0.7	0.7	2-7
ESR, mm/h	38.0	60.9	35.1	29.6	0-21
AST, U/L	42.1	33.4	17.8	25.5	6-58
ALT, U/L	76.0	51.2	18.8	29.5	14-67
ALP, U/L	98.0	135.1	101.4	52.6	38-150
Total bilirubin, mg/dL	0.7	5.6	1.1	0.5	0.3-1.2
Albumin, g/dL	4.5	2.7	4.1	3.2	3.4-4.7
Direct bilirubin, mg/dL	0.4	4.2	0.9	0.3	0.1-0.4
Serum sodium, mmol/L	135	137	132	141	134-144
Serum potassium, mmol/L	3.3	3.1	4.8	5.0	3.5-5.1
Serum creatinine, mg/dL	1.2	1.1	1.2	1.5	0.6-1.7
TSH, IU/mL	N/A	1.3	2.5	1.0	0.36-3.7
Free T4, pg/mL	N/A	1.2	2.5	0.9	0.7-1.6

ALP: Alkaline phosphatase; ALT: Alanine aminotransferase; AST: Aspartate transaminase; ESR: Erythrocyte sedimentation rate; N/A: Not available; TSH: Thyroid-stimulating hormone

Fever is one of the most common symptoms of toxocariasis, but fever was found in three of the four cases. Therefore, ocular larva migrans syndrome has to be taken into consideration even in the differential diagnosis of patients without eosinophilia, fever with ocular involvement.

Ocular toxocariasis occurring age may be vary from one to 70 years of age; however, it is mostly seen at the age of less than 15 old years and can cause permanent vision loss. The disease usually affects one eye and typically presents as posterior pole granuloma, peripheral granuloma, nematode endophthalmitis and optic neuritis.

Definite diagnosis and subsequent treatment of OLM is difficult to be made as identification of larvae has been rarely done (11). Ocular form of toxocariasis is usually diagnosed by clinical finding on ophthalmologic examinations by ophthalmologist (12). Therefore, its detection can be challenging, because both the condition is relatively uncommon and its presentation varies from patient to patient. Diagnosis of ocular toxocariasis is based on clinical and ophthalmological examination as well specific laboratory findings. A specific ELISA for detection of anti-*Toxocara* antibodies in the serums and intraocular fluid using *Toxocara*

excretory-secretory (ES) antigen has been proven (6,13,14).

Granuloma either in the posterior pole or in the periphery, endophthalmitis, and pars planitis were several ocular manifestations of ocular toxocariasis that have been proven (15,16). The demonstrating of a higher anti-*Toxocara* titer in the vitreous of patients with ocular toxocariasis when compared to the serum represents definitely migratory ocular larva syndrome. In the cases discussed here, four case with blurred vision and visual impairment ocular toxocariasis diagnosed by the detection of specific antibodies to *T. canis* in the serum and vitreous fluid was report.

Conclusion

Although ocular form of toxocariasis is a rare condition, ophthalmologists need to be made aware of ocular toxocariasis especially in-suspected people and should consider *Toxocara* as a causative agent of posterior and diffuse uveitis and in differential diagnosis. There are many differential diagnoses for ocular toxocariasis like retinoblastoma, traumatic, bacterial, fungal endophthalmitis, retinopathy of prematurity and subacute neuroretinitis,

so a correct and quick diagnosis and treatment is very important.

Acknowledgements

Authors want to acknowledge the staff of Ophthalmology Clinics and Parasitology Laboratory of Alborz University of Medical Sciences for technical assistance provided.

Conflict of interest

The authors declare that there is no conflict of interest.

References

1. Smith H, Holland C, Taylor M, et al. How common is human toxocariasis? Towards standardizing our knowledge. *Trends Parasitol.* 2009;25(4): 182-8.
2. Zibaei M, Sadjjadi SM. Trend of toxocariasis in Iran: a review on human and animal dimensions. *Iran J Vet Res.* 2017;18(4):233-242.
3. Ahn SJ, Ryoo NK, Woo SJ. Ocular toxocariasis: clinical features, diagnosis, treatment, and prevention. *Asian Pacific Allergy.* 2014;4(3):134-141.
4. Zhang T, Guo D, Xu G, et al. Ocular Toxocariasis: Long-Term Follow-Up and Prognosis of Patients following Vitrectomy. *Ocul Immunol Inflamm.* 2020;28(3):517-523.
5. Zibaei M, Sadjjadi SM, Jahadi-Hosseini SH. *Toxocara cati* larvae in the eye of a child: a case report. *Asian Pac J Trop Biomed.* 2014;14(Supp 1):S53-S55.
6. Huang L, Sun L, Liu C, et al. Diagnosis of ocular toxocariasis by serum and aqueous humor IgG ELISA. *Transl Vis Sci Technol.* 2021;10(8):33.
7. Chai JY, Jung BK, Hong SJ. Albendazole and mebendazole as anti-parasitic and anti-cancer agents: an update. *Korean J Parasitol.* 2021;59(3):189-225.
8. Guillot J, Bouree P. [Zoonotic worms from carnivorous pets: risk assessment and prevention]. *Bull Acad Natl Med.* 2007;191(1):67-78.
9. Stewart JM, Cubillan LD, Cunningham ET Jr. Prevalence, clinical features, and causes of vision loss among patients with ocular toxocariasis. *Retina.* 2005;25(8):1005-13.
10. Badri M, Eslahi AV, Olfatifar M, et al. Keys to unlock the enigma of ocular toxocariasis: a systematic review and meta-analysis. *Ocul Immunol Inflamm* 2021; 29(7-8):1265-1276..
11. Martínez-Pulgarín DF, Muñoz-Urbano M, Gomez-Suta LD, et al. Ocular toxocariasis: new diagnostic and therapeutic perspectives. *Recent Pat Antiinfect Drug Discov.* 2015;10(1):35-41.
12. Dietrich CF, Cretu C, Dong Y. Imaging of toxocariasis. *Adv Parasitol.* 2020;109:165-187.
13. Rubinsky-Elefant G, Hirata CE, Yamamoto JH, et al. Human toxocariasis: diagnosis, worldwide seroprevalences and clinical expression of the systemic and ocular forms. *Ann Trop Med Parasitol.* 2010;104(1):3-23.
14. Zibaei M, Sadjjadi SM, Karamian M, et al. A comparative histopathology, serology and molecular study, on experimental ocular toxocariasis by *Toxocara cati* in Mongolian gerbils and Wistar rats. *Biomed Res Int.* 2013;2013:109580.
15. Hernanz I, Moll-Udina A, Llorenç BV, et al . Ocular Toxocariasis: beyond typical patterns through the new imaging technologies. *Ocul Immunol Inflamm.* 2020; 29(7-8):1-7.
16. Li S, Sun L, Liu C, et al. Clinical features of ocular toxocariasis: a comparison between ultra-wide-field and conventional camera imaging. *Eye (Lond).* 2021;35(10):2855-2863.