



Tehran University of Medical  
Sciences Publication  
<http://tums.ac.ir>

## Iran J Parasitol

Open access Journal at  
<http://ijpa.tums.ac.ir>



Iranian Society of Parasitology  
<http://isp.tums.ac.ir>

### Case Report

## Using Maggot Debridement Therapy in Treatment of Necrosis in the Forearm Caused By Docetaxel Extravasation: A Case Report

Dariusz Bazaliński<sup>1,2</sup>, Joanna Przybek-Mita<sup>2,3</sup>, \*Marek Kucharzewski<sup>4</sup>, Paweł Więch<sup>2,5</sup>

1. Father B. Markiewicz Podkarpackie Specialist Oncology Centre, Specialist Hospital in Brzozów, Brzozów, Poland
2. Institute of Health Sciences, College of Medical Sciences, University of Rzeszów, Rzeszów, Poland
3. Centre for Post-Graduate Education of Nurses and Midwives, Rzeszów, Poland
4. Department of Descriptive and Topographic Anatomy, Medical University of Silesia, Katowice, Poland
5. Institute of Social Sciences and Health Protection, East European State Higher School in Przemyśl, Przemyśl, Poland

Received 08 Mar 2021

Accepted 19 May 2021

#### Keywords:

Maggot debridement therapy;  
Larvae;  
Cytostatics extravasation

#### \*Correspondence

##### Email:

[p.k.wiech@gmail.com](mailto:p.k.wiech@gmail.com)

#### Abstract

Extravasation of doxorubicin, vincristine or vinblastine leads to necrosis, damage of the muscles and nerves, deep ulceration, as well as limb dysfunction. Necrosis and deep ulcers develop within 7 to 28 days. Like necrotomy, *Lucilia sericata* maggot therapy is recognised as a method enabling effective, safe and quick removal of necrotic tissue. The purpose of the study was to present local treatment of hypodermic necrosis caused by docetaxel extravasation in course of systemic cancer therapy. A woman, 59 years of age, in course of systemic therapy due to advanced cancer of the left breast (T2N1M1 CS IV) with confirmed metastases within the body of the fourth lumbar vertebra and in the liver, receiving a combination treatment with pertuzumab, trastuzumab, and docetaxel. During the therapy, a conservative treatment was applied due to extravasation for over three months. Effects in the right forearm included swelling, redness, signs of 4x10cm inflammatory infiltrate, with 1x4cm necrotic crust visible in the central region. Hypodermic necrosis was debrided using *L. sericata* maggots, and subsequently specialist dressings were applied to promote granulation and healing. In the case discussed here, effectiveness of MDT was rather poor, however the treatment minimised the risk of infection associated with evacuation of necrosis. Attempts to use MDT should be continued to enable more comprehensive understanding of problems related to management of necrosis in wounds developing during cancer therapy.



## Introduction

Chronic conditions, such as cancer, associated with uncertain prognoses, require a holistic approach to the patient management, including application of a systemic treatment. Although such approach gives a chance of recovery, it may also carry a risk of undesirable symptoms and complications. These include localized reactions following extravasation of cytostatic agents that is leakage from the veins. Extravasation occurs in 0.1–7% cases of intravenous administration of cytotoxic drugs, with the rate of serious consequences in the range of 0.01–1% (1), or from 0.26% to 4.7% following administration via the central vein (2).

Patients receiving cytostatic and cytotoxic drugs are at risk of extravasation due to frequent intravenous injections, inflammation processes in blood vessels, lymphedema, or cachexia. Extravasation of cytostatic agents producing damaging effect (docetaxel, paclitaxel, doxorubicin, vincristine or vinblastine) leads to necrosis, damage of the muscles and nerves, deep ulceration, as well as limb dysfunction. Necrosis and deep ulcers develop within 7 to 28 days. This usually leads to skin necrosis, damage to the muscles and nerves as well as deep ulceration. These symptoms are accompanied with limb dysfunction (1,3).

Like necrotomy, Maggot Debridement Therapy (MDT) is recognized as a method enabling effective, safe and quick removal of necrotic tissue (4). It is more and more commonly applied in both outpatient and inpatient treatments in many countries worldwide. The therapy is recommended for use in the case of various types of infected or necrotic wounds where the standard surgical intervention is not recommended or its effectiveness would be uncertain or relatively low for the patient. Clinical observations explicitly show that by using the maggot therapy it is possible to reduce the duration of the process and to remove necrotic tissue from the wound with

great precision, compared to the conventional methods involving application of surgical interventions and specialist dressings (hydrogels, and hydrofibers) (5,6). Increased interest in MDT also results from the growing antibiotic resistance of infected chronic wounds and poor effectiveness of the conventional methods (4).

The purpose of the study was to present local treatment of hypodermic necrosis caused by docetaxel extravasation in course of systemic cancer therapy. The patient received the treatment in home setting and at an outpatient facility, in compliance with the guidelines and recommendations for patient management during COVID-19 pandemic.

## Case report

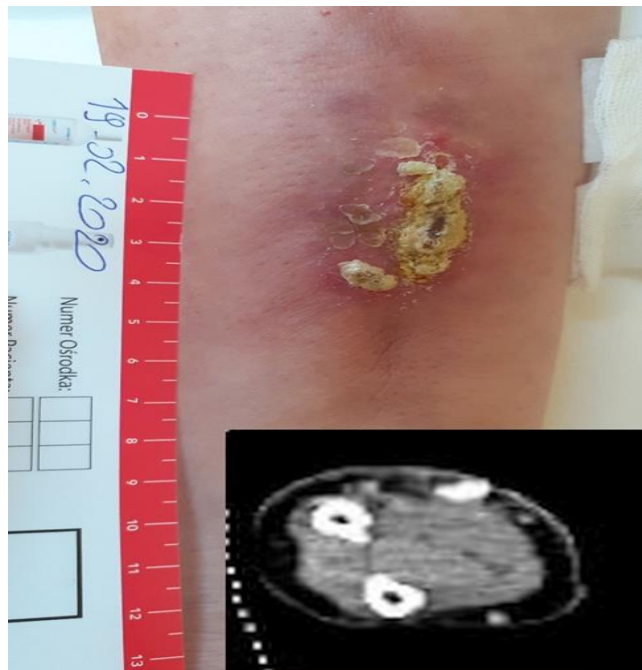
The present study focused on the case of a 59-year-old woman, in course of systemic therapy due to advanced cancer of the left breast (T2N1M1 CS IV) with confirmed metastases within the body of the fourth lumbar vertebra and in the liver, receiving a combination treatment with pertuzumab, trastuzumab, and docetaxel (Perjeta® (Roche) 420 mg, Herceptin® (Roche) 600 mg, Docetaxel® (Accord Healthcare) 120 mg)). She referred to Specialist Hospital in Brzozów, Brzozów, Poland.

In October 2019, during the third cycle of chemotherapy, difficulties were encountered during administration of docetaxel via the peripheral venous access in the front of the forearm. The needle insertion placement was changed while no extravasation was clinically confirmed. A few days later, redness, swelling and soreness appeared in a 4x12 cm area corresponding to the location of the first vein puncture. A local treatment applied by a dermatologist included Dermisil® (Polpharma) (acidum fusidicum plus betamethasonum) administered for 10 days, followed with Ar-

gosulfan® (PharmaSwiss/Valeant) (Sulfathiazolum argentum). A few centimeter-long linear scab appeared in the central area of the lesion. The treatment was continued without effect for over three months. In the meantime, the patient's chemotherapy was continued via a newly implanted venous access port.

In February 2020 the patient was referred to a chronic wound care clinic for assessment of the lesion on her forearm. The examination (19 Feb.) showed the patient was capable of auto- and allopsychic orientation, as well as self-care (Barthel Index 85 points). Symptoms

visible in the right forearm included swelling, redness, and signs of 4x10cm inflammatory infiltrate, with 1x4cm necrotic crust visible in the central region, as well as a high risk of infection, 3 points in WAR (Wound at Risk) scale. The assessment also showed symmetric and normal range of motion in the joints and muscle strength of the limb. A request was made for computed tomography of the forearm, to be performed during radiological assessment of the cancer therapy (22 Feb.) (Fig. 1).



**Fig. 1:** The wound on the day the patient was admitted for the local wound care; in the bottom right corner - CT scan

Biochemical examinations showed the following results: red blood cells (RBC) 4.12 million/ $\mu\text{l}$  [4.0–5.5 million/ $\mu\text{l}$ ], hemoglobin (HGB) 12.8 g/dl [12.0–18.0 g/dl], white blood cell (WBC) 4.3/ $\mu\text{l}$  [4.0–10.0/ $\mu\text{l}$ ] and hematocrit (HCT) 38.5% [36.0–55.0%], C reactive protein (CRP) 2.8 mg/l [0–5 mg/l], and creatinine 65,0  $\mu\text{mol/l}$  [44–80  $\mu\text{mol/l}$ ]. The patient was informed about the possible treatment which would involve opening of the wound and its debridement with *Lucilia sericata*

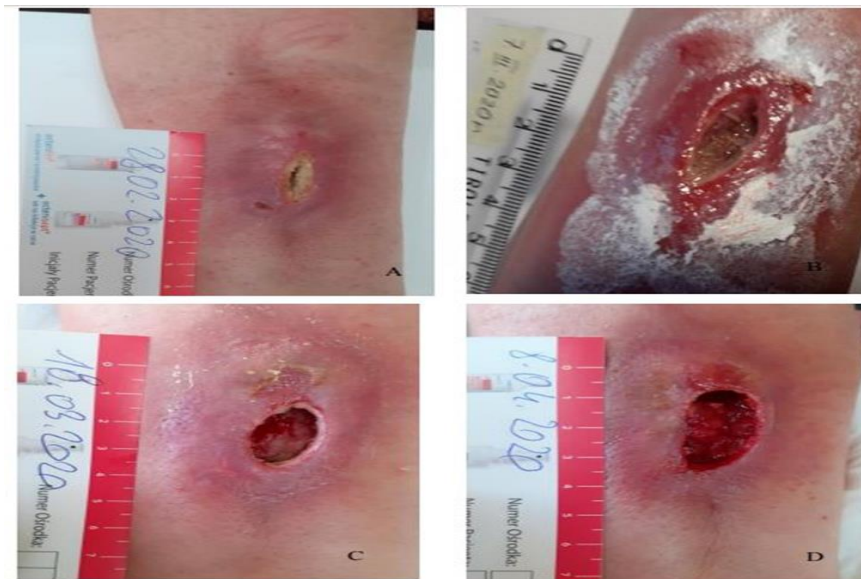
maggots, to be followed with application of specialist dressings promoting granulation and healing of the wound. The patient's attitude towards this method was assessed with MDT acceptance questionnaire which showed high level of motivation and the patient's consent for the therapy. Consequently, the damaged skin was opened by incision and gentle dissection of tissue layers. Necrotic subcutaneous tissue was revealed; the wound was drained using silver-impregnated mesh dressing (At-

rauman Ag®, Hartmann). The maggots were ordered from Biolab Polska; one day before the application, the use of antiseptic was discontinued. Ultimately, 25-30 free-range maggots were used (28 Feb.). Zinc ointment was applied to the skin around the wound to secure it against chemical irritation produced by the maggots. At the time the dressings were applied, the skin was secured with lubricating and protective agents Ozonella® (Onkomed) and Arcalen® (Herbapol).

It was observed that the larvae in the wound were not very aggressive, their food intake was low and they did not grow; only a few living larvae were removed from the wound on the third day of the therapy. It was speculated that the poor effectiveness of the larvae in the wound was linked with poor quality of the colony. A few days later (6 March) another batch of 25-30 larvae was placed in the wound. Again, very poor therapeutic effect was observed, the larvae debrided only a small part of the wound, revealing its base (approximately 20-30% of the necrotic tissue). At the same

time larvae from the same culture were applied in other patients, and in that case effectiveness of the debridement process exceeded 70%, which disproved the assumption about the “poor quality colony”. After evacuation of the larvae, the liquefied necrotic tissue was removed with a curette, and antiseptic gel Prontosan® (B.Braun Melsungen) as well as hydrofiber dressing Durafiber® (Smith & Nephew) were applied to the wound. Although high effectiveness of MDT was no longer expected, 25-30 larvae were applied for the third time (18 March); again only a few larvae survived until the third day, they were slow to feed, however this time most of the necrotic tissue was debrided, and the liquefied residues were again removed with a curette from the subcutaneous compartment.

In order to avoid a wider opening of the wound, the subcutaneous necrotic tissue was evacuated via 2x1cm opening in the outer skin layer (Fig. 2).



**Fig. 2:** Stages of wound healing; A. The wound before the first application of larvae; visible redness and swelling; palpation identified soreness 1-3 score in NRS. B. Day Two following the first application of the larvae; visible clustering of the larvae in the wound. C. The wound before the third application of larvae; visible red and yellow bottom of the wound; the compartment with compact necrotic tissue reaching 3-5 centimetres below the skin. D. Granulation tissue covering the wound, with the compartment visible at 12 o'clock, extending approximately 4 cm towards the elbow

A few days after the wound was cleansed, scrapings were collected for microbiological examination which confirmed presence of *Proteus vulgaris* ( $10^4$ ) and *Staphylococcus aureus* ( $10^4$ ), i.e. bacteria sensitive only to gentamicin and ciprofloxacin. In view of the patient's decreased immunity due to the ongoing cancer therapy, the prescribed medication included Ciprinol (Krka) 2x500 mg, to be administered orally (10 days) as well as (off-label) gentamicin in vials (Krka) to be applied to the wound on hydrofiber dressing, at a dose of 15 mg for 10 days. The dressings were changed every two days, and during the procedure the wound tissue was carefully scraped. After the necrosis was eliminated, the healing proceeded without complications despite the continued oncological treatment (in April the patient was operated due to metastasis to the pituitary gland); the wound was closed on 5 May 2020 (Fig. 3).

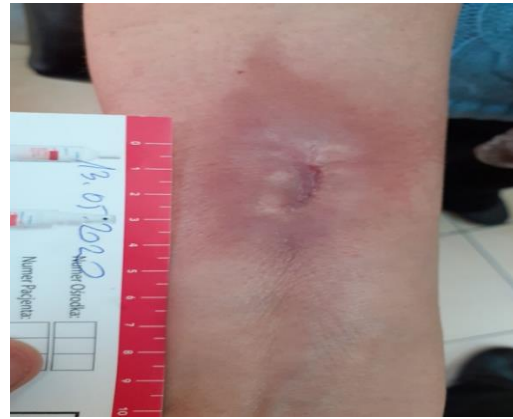


Fig. 3: Healing process completed in the wound resulting from extravasation, status on 13 May 2020

The wound therapy was continued for 75 days; the design of the therapeutic operations in the local wound treatment is shown in a graphic way in Fig. 4.

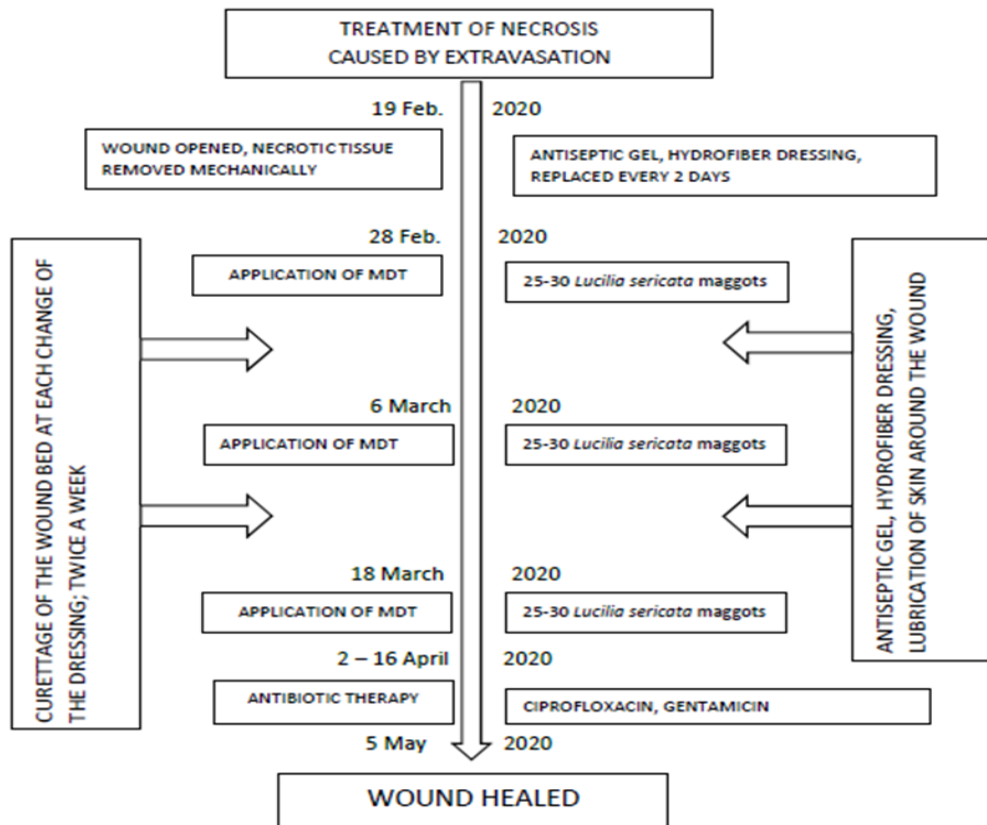


Fig. 4: Therapeutic operations performed in course of local wound care.

## Discussion

Proceeding in the case of extravasation of cytotoxic and cytostatic drugs is subject to guidelines proposed by scientific societies (European Oncology Nursing Society - EONS, European Society for Medical Oncology - ESMO), and although these recommendations are controversial, they set the direction and define the related procedures to be followed in specific cases (7). Controlled clinical extravasation trials cannot be conducted for ethical reasons. Of key importance are preventive operations and broadly understood prophylaxis aimed at reducing the risk of tissue destruction and the related problems. In the case of extravasation caused by Vinca alkaloid and taxoid drugs the recommended treatments include hyaluronidase and warm compress and well as elevation of the limb for 24 hours (1,7).

Undesirable skin-related effects of docetaxel extravasation which have been described in the literature include irritant damage with pigmentary changes, desquamation or swelling, vesicant local reactions varying from erythema to necrosis, palmar-plantar erythrodysesthesia, as well as bilateral dermatitis in axillae or groins (8,9). In the case discussed here, despite the concern reported by the patient, no preventive measures were taken because of the lack of clinical symptoms. In the context of cancer therapy and possibly weakened immune system, it seems justified and legitimate to conduct observations and apply local therapies, or to delay surgical interventions.

When the patient was admitted into the chronic wound care clinic, she was informed in detail about the options for local treatment and the possible complications associated with infection, in course of the wound cleansing. MDT was suggested as it involves biochemical activity connected with production of digestive enzymes in the collagenase group as well as bactericidal and antibiofilm substances such as Lucifensin I, II, Chymotrypsin I, and

DNase (10,11). Since the use of MDT may be associated with unpleasant mental experiences, a case assessment was carried out prior to larvae application, using a questionnaire which was described and introduced to clinical practice (12). The good motivation for using the therapy was the determinant for the therapeutic success. During the maggot therapy the patient reported mild pain (1-3 NRS), which did not require administration of analgesics. A risk of damage to the epidermis was decreased by application of zinc ointment to the skin. The procedures of larvae application and inspection of dressings were conducted in accordance with the treatment model developed by this author (10).

Effectiveness of the wound cleansing process was poor, which was observed following the first application; this may have resulted from the fact that the extravasation was connected with docetaxel, an agent in the group of taxanes whose activity involves suppression of cell division. Docetaxel reduces the growth and development of neoplasm. It was stipulated that the poor growth and death of the larvae may have been caused by the cytotoxicity of the necrotic tissue which the maggots were to eliminate by feeding on it. Of significance here is the type of dead tissues to be removed. Experience of these authors suggests that dead muscle and skin tissues provide excellent nourishment for maggots, while tendons and fasciae are assimilated less effectively – this seems to be reflected by the growth of maggots on the specific days of a therapy continued for up to 3-4 days. By comparison, these authors reported 70% effectiveness of wound debridement therapy applied in home setting. The 200 cm<sup>2</sup> wound in the forearm, resulting from extravasation of calcium chloride, was debrided in 72 hours with the use of 100 larvae (10). This suggests good potential of MDT. These authors' observations, however, suggest that MDT cannot be applied to each patient with a necrotic wound, and this is consistent with

opinions expressed by many researchers investigating medical use of maggots (13).

Topical administration of antibiotic to skin affected by a disease is a frequent procedure in dermatology (14), however this approach is not effective, and is controversial when it comes to treatment of chronic wounds particularly those of large size. Topical antibiotics present numerous benefits since they come in direct contact with pathogenic bacteria and reduce a risk of systemic side effects while presenting a wide spectrum of antimicrobial activity owing to the high concentrations of the active ingredient at the location in which they are applied (15). Topical administration initially leads to high concentrations at the relevant location, without causing toxic levels in the blood serum, yet it poses a risk of inducing resistance and produces bacteriostatic effect at concentrations which are difficult to control in the case of topical application. The agents used in the relevant case included ciprofloxacin (administered orally), as well as (off-label) gentamicin applied at a dose of 15 mg (3 mg/1cm<sup>2</sup>) on hydrofiber dressing, and in course of 10 days there was a decrease in fibrin and a rapid decrease in the size of subcutaneous compartment owing to growth of granulation tissue.

In the literature there are very few studies investigating effectiveness of gentamicin administered topically. Feasibility of dressing impregnated with gentamicin has not been extensively investigated, except in some cases of osteomyelitis (16); the method has also been recommended for use in treatment of chronic infections in patients with diabetic foot (17). The consensus published by Kramer et al. recommends that combinations of antiseptics be used in local treatment of wounds highly at risk of infection (14), however in specific difficult cases antiseptics prove to be ineffective and systemic administration of an antibiotic produces insufficient benefits for the patient. Given the

above, in this case the authors decided that efficacy of topical administration should be assessed in course of the controlled observation. The applied procedure proved to be effective, the wound was healed while the systemic cancer therapy was continued, and the patient's self-reported quality of life was greatly improved.

## Conclusion

In the case discussed here, effectiveness of MDT was rather poor; however, the treatment minimized the risk of infection associated with evacuation of necrosis. Attempts to use MDT should be continued to enable more comprehensive understanding of problems related to management of necrosis in wounds developing during cancer therapy.

## Acknowledgements

We would like to express our sincere appreciation to Jadwiga Ryba for the language assistance.

## Conflict of interest

The authors declare no conflict of interest.

## References

1. Rubach M. Management of extravasation of antineoplastic agents. *Oncol Clin Pract.* 2018; 14(1):15–22.
2. Kreidieh FY, Moukadem HA, Saghier NE. Overview, prevention and management of chemotherapy extravasation. *World J Clin Oncol.* 2016; 7(1):87-97.
3. Pérez Fidalgo JA, García Fabregat L, Cervantes A, et al. Management of chemotherapy extravasation: ESMO-EONS Clinical Practice Guidelines. *Ann Oncol.* 2012; 23:167-73.
4. Wollina U, Liebold K, Schmidt W, et al. Bio-surgery supports granulation and debridement in chronic wounds - Clinical data and remit-

- tance spectroscopy measurement. *Int J Dermatol.* 2002; 41(10):635–9.
5. Sherman R, Shimoda K. Presurgical maggot debridement of soft tissue wounds is associated with decreased rates of postoperative infection. *Clin Infect Dis.* 2004; 39(7): 1067-70.
  6. Yan L, Chu J, Li M, et al. Pharmacological Properties of the Medical Maggot: A Novel Therapy Overview. *Evid Based Complement Alternat Med.* 2018; 3:4934890.
  7. Kreidieh FY, Moukadem HA, El Saghir NS. Overview, prevention and management of chemotherapy extravasation. *World J Clin Oncol.* 2016;7(1):87–97.
  8. Gallo E, Llamas-Velasco M, Navarro R, et al. Eccrine squamous syringometaplasia secondary to cutaneous extravasation of docetaxel: report of three cases. *J Cutan Pathol.* 2013; 40(3):326–9.
  9. Pei-Hung C, Mei-Ti W, Yi-Hua C, et al. Docetaxel extravasation results in significantly delayed and relapsed skin injury: A case report. *Oncol Lett.* 2014; 7:1497-1498.
  10. Bazaliński D, Kózka M, Karnas M, et al. Effectiveness of Chronic Wound Debridement with the Use of Larvae of *Lucilia sericata*. *J Clin Med.* 2019; 8(11):1845.
  11. Brown A, Horobin A, Blount DG, et al. Blow fly *Lucilia sericata* nuclease digests DNA associated with wound slough/eschar and with *Pseudomonas aeruginosa* biofilm. *Med Vet Entomol.* 2012; 26(4):432–9.
  12. Bazaliński, D. Evaluation of the effectiveness of *Lucilia sericata* larvae treatment in wound tissue debridement in the process of chronic wound treatment in patients subjected to long-term and palliative care. Rzeszow: University of Rzeszow; 2019. [https://katalogi.bn.org.pl/permalink/48OMNIS\\_NLOP/1aot9i7/alma991052518720305066](https://katalogi.bn.org.pl/permalink/48OMNIS_NLOP/1aot9i7/alma991052518720305066)
  13. Sun X, Jiang K, Chen J, et al. A systematic review of maggot debridement therapy for chronically infected wounds and ulcers. *Int J Infect Dis.* 2014; 25:32–7.
  14. Ahronowitz I, Harp J, Shinkai K. Etiology and management of pyoderma gangrenosum: a comprehensive review. *Am J Clin Dermatol.* 2012; 13(3):191-211.
  15. Friedman B, Goldman D. Anti-staphylococcal treatment in dermatitis. *Can Fam Physician.* 2011; 57(6):669–671.
  16. Eklund AM. Prevention of sternal wound infections with locally administered gentamicin. *APMIS.* 2007; 115(9):1022–1024.
  17. Varga M, Sixta B, Bem R, et al. Application of gentamicin-collagen sponge shortened wound healing time after minor amputations in diabetic patients - a prospective, randomized trial. *Arch Med Sci.* 2014; 10(2):283–7.