



Tehran University of Medical
Sciences Publication
<http://tums.ac.ir>

Iranian J Parasitol

Open access Journal at
<http://ijpa.tums.ac.ir>



Iranian Society of Parasitology
<http://isp.tums.ac.ir>

Original Article

Histological Changes of the Ovary in Pregnant Mice Vaginally Exposed to *Toxoplasma gondii*

Zahra ESLAMIRAD¹, *Parvin-Dokht BAYAT², Saeid BABAEI²

1. Dept. of Parasitology, School of Medicine, Arak University of Medical Sciences, Arak, Iran
2. Dept. of Anatomy, School of Medicine, Arak University of Medical Sciences, Arak, Iran

Received 10 Jan 2015
Accepted 23 Apr 2015

Keywords:
Corpus luteum,
Histology,
Ovarian follicles,
Toxoplasma gondii

***Correspondence**
Email:
dr.bayat@arakmu.ac.ir

Abstract

Background: Congenital toxoplasmosis is one cause of abortion. Infection can disrupt ovarian cycles and because toxoplasmosis is an infectious disease may have a similar effect on the ovaries. The purpose of this study was to investigate the pathological changes in the ovaries due to toxoplasmosis.

Methods: Tachyzoites of *Toxoplasma gondii* were harvested from peritoneal fluid of mice, experimentally infected. Two females and one male mouse were housed per cage for mating in the overnight. The pregnant mice were divided into experimental and control groups. Experimental group were infected by parasite but the control group received the normal saline. The experimental and control mice were euthanized. Ovaries and uterine horns of animals were removed and prepared for light microscopy.

Results: Ovaries of infected pregnant mice presented gross morphological differences compared to the control groups. In ovaries of experimental groups, changes of corpus luteum were observed. The comparison of experimental and control groups revealed that the number of primary follicles, secondary follicle, atretic primary follicles and atretic secondary follicles had significant differences ($P \leq 0.001$).

Conclusion: *Toxoplasma gondii* alters ovarian follicular growth and development in mice. In addition, it alters number of different phases of follicles and corpus luteum in ovaries of mice.

Introduction

Toxoplasmosis is a common disease in humans, domestic and wild animals (1, 2). Congenital toxoplasmosis is one of the principal etiologic factors for abor-

tion (3). The mechanism of abortion due to toxoplasmosis is not fully defined, and the effects of this parasite on corpus luteum function have not been explored (4). Infection dis-

rupts ovarian cycles and may reduce fertility. In normal rats, infection could inhibit ovulation (5). Since toxoplasmosis is an infectious disease may has similar effects on the ovarian function. In addition, chronic infection influences noradrenergic mechanisms in hypothalamus; which may be responsible for reduced reproductive activity (6).

Since *Toxoplasma* could also be deployed in brain tissue, it could affect the function of different parts of the brain like hypothalamus (6). Transient hypogonadism and testosterone changes may be observed in men with toxoplasmosis (7, 8). The change of serum and salivary testosterone levels in *Toxoplasma*-infected men and women is confirmed (9). Although the mechanism of relationship between testosterone and toxoplasmosis is important but the process is not clear (10). Histological examination of *Toxoplasma*-infected female mice showed distinct hypertrophy of the endometrium and myometrium. The result of Fux study on *Toxoplasma*-infected mice compared to the uninfected animals showed that “a tendency for a reduction in folliculogenesis and the formation of corpora lutea in the ovaries” (11). Coutinho et al. sought the mechanisms involved in poor pregnancy outcome when animals are infected by *Toxoplasma*. Since pathological changes in the placenta are more common and severe than in the fetus, it seems that placental damage is probably the primary cause of fetal death (12).

Epidemiological studies have shown high prevalence of toxoplasmosis in Iran (13, 14). Molecular methods have confirmed the presence of *Toxoplasma gondii* in tissues of ovary and uterus of mice, infected vaginally (15). The purpose of this study was to investigate the pathological changes in the ovaries due to toxoplasmosis.

Materials and Methods

Mice

Eight to 12 wk old female NMRI mice were obtained from Pasteur institute of Iran. The

mice were maintained in polyethylene cages with free access to food and water in a room with controlled humidity and temperature (22– 24 °C) on a 12-h light/dark cycle. Two females and one male were housed per cage for mating in the overnight. Observation of vaginal plug designated as first day of pregnancy (P/1). Pregnant females were removed from the mating cages.

This study was approved by the Medical Ethical Committee of Arak University of Medical Sciences, Arak, Iran (Code no. 607).

Parasite

The RH strain of *Toxoplasma gondii* was provided by Department of Parasitology, Faculty of Health, Tehran University of Medical Sciences. Tachyzoites of parasite were harvested from peritoneal fluid of white mice which 4 days earlier had been experimentally infected. These parasites were used for infection of experimental animals via intra-vaginal (IV) in first day of pregnancy.

Experimental infection and pregnancy outcome

The pregnant mice were divided into 2 groups: 1) Experimental group that infected by 15 µl of normal saline containing parasite (contain 5×10^5 parasite) via intra-vaginal (IV). 2) Control group that received the same volume of normal saline via IV. Procedure of intra-vaginal inoculation was described previously (15). Experimental group were inoculated on the first day of pregnancy. Each group divided into 3 subgroups.

The experimental and control females were euthanized and examined on day 4 p.i. (post infection) , day 9 p.i. and day 16 p.i.

Each experimental subgroup constituted at least six animals. After euthanasia by cervical dislocation, ovaries and uterine horns were removed from each animal.

Tissue preparation for light microscopy (LM)

A: Right ovary organ of experimental and control groups were fixed in 10% formalin for

48 hour. Before fixation, the tissues were briefly washed with saline and then excised tissues were fixed in formalin (pH 6.8) and embedded in paraffin. Sectioning was conducted in 5 μ m thickness by microtome from ovary organ totally. Five similar sections were selected from each ovary randomized. The sections of each paraffin block were stained with Hematoxylin and Eosin (16). Finally, sections were studied and photographed with light microscopy in this relation a10 \times 100 objective lens were used to capture photos (NIKON Eclipse E2000-Videocamera DS-Fi1, Japan). All chemical were purchased from Merck (Co. Germany).

B: The sections were observed under light microscopy. Healthy and atretic follicles were evaluated with Image Tool (UTHSCSA, Version 2.03-alpha 6). According to Jolly et al. and Fortune et al. (17, 18) all healthy follicles, with intact oocytes, were classified in: a) number of primary follicles, without follicular antrum, b) number of secondary follicle, showing follicular antrum, C) number of atretic primary follicles, (D) number of atretic secondary follicles, E) number of corpus luteum. The atretic follicles (C and D) were characterized by degenerating oocytes, disorganized granulosa cell layers, folded zona pellucida, partially or completely separated from corona radiata and from granulosa cells of the oocyte as well. Apoptotic bodies were common inside, outside the oocytes, and in granulosa cells (19). The degenerating primordial or primary follicles were termed atretic follicles and those with degeneration in the secondary of graaf follicles, atretic secondary follicles. The number of all type of follicles and corpus luteum bodies per ovary were counted with imaging software Image tools (Uthscsa , version 3) .

Statistical Analysis

The mean \pm SD of each variable was studied in experimental and control groups and the statistically significant difference was determined with Kruskal Wallis and U Mann Whitney tests .The analysis was performed

between the groups by Oneway ANOVA test ($P < 0.05$).

Results

Effects of toxoplasmosis on ovarian morphology

Ovaries of pregnant mice that were vaginally infected by *Toxoplasma* presented gross morphologic differences compared to those of the control groups. The primary and secondary healthy follicles and corpus luteum of the control groups showed normal appearance (Fig. 1A). All ovarian sections in experimental groups showed great defects in follicles, atretic follicles and corpus luteum in developmental stages (Fig. 1B). Furthermore, in these groups some of the primary follicles showed normal appearance, although with high congestion compared to the control group (Fig. 1B).

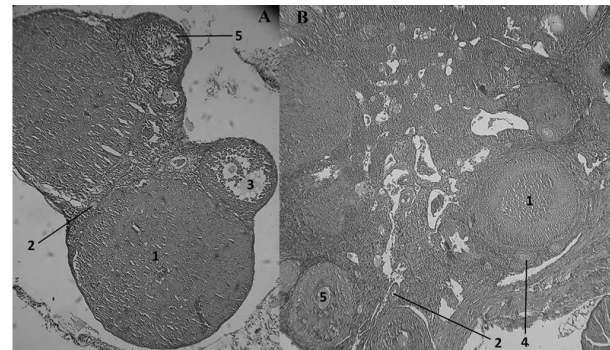


Fig.1: The section of ovary in mice in 16th day of pregnancy. **A.** Mice ovary in control group (10 \times 10). **B.** Mice ovary in experimental group (10 \times 10). 1) Corpus luteum , 2) Primary follicle 3) secondary follicle 4) Atretic primary follicles 5) Atretic secondary follicles

Atretic primary follicles presented retracted primary oocytes with vacuolated cytoplasm, eccentric nucleoli, and an irregular membrane. The zona pellucida was disintegrated in many areas and the granulosa cells were disaggregated. Granulosa cells were observed around the oocytes with piknotic nuclei the corona radiata cells were detached from the zona pel-

lucida, which was folded. In general, the tissue sections in subjects compared to the controls, increased follicle atresia (Fig. 1B).

In ovaries of experimental groups were observed the effects of toxoplasmosis on corpus luteum as polyhedral luteal cells, higher staining of paraluteal cells, increased heterochromatin, a prominent nucleolus, cytoplasmic inclusions with vacuolar appearance, and poor staining (Fig.1B). Generally the number of

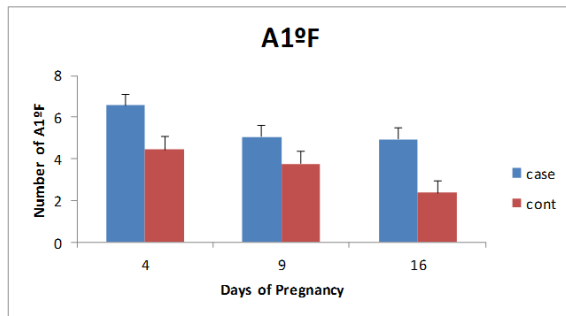


Fig 2: The comparison of number of atretic primary follicles in experimental and control groups at 4, 9 and 16 days of pregnancy

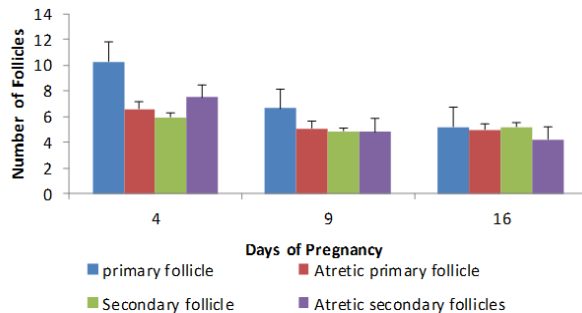


Fig 4: The comparison of number of follicles (primary and secondary follicle, atretic primary and secondary follicles) in 4, 9 and 16 days of pregnancy in the experimental groups

As shown in Fig.3, comparing experimental and control groups, the number of atretic secondary follicles is higher than the experimental group.

According to Fig.4, comparing experimental groups, the maximum number of atretic primary follicles and atretic secondary follicles were shown on the fourth day of pregnancy.

corpus luteum in experimental group is reduced compared to the control by increasing gestational age, but this decrease is not regular (Fig. 1B).

As shown in Fig.2, comparing experimental and control groups, the number of atretic primary follicles is higher than the experimental group. As shown in Fig. 2, the number of atretic primary follicles decreases with increasing gestational age.

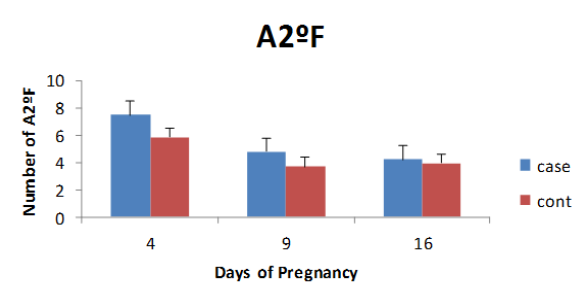


Fig3: The comparison of number of atretic secondary follicles in experimental and control groups at 4, 9 and 16 days of pregnancy

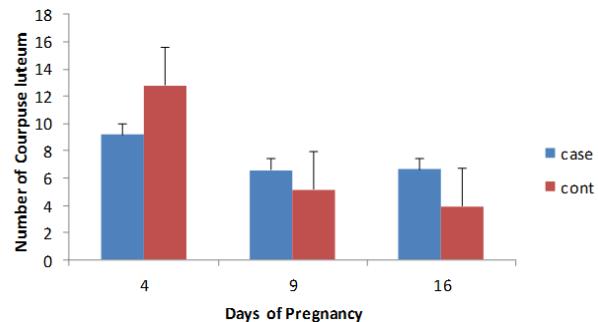


Fig 5: The comparison of corpus luteum number in experimental and control groups

Effects of toxoplasmosis on number of atretic follicles and corpus luteum

Comparing the experimental and control groups revealed that the number of all type of follicles (primary and secondary follicle, atretic primary and secondary follicles) had significant differences ($P \leq 0.001$).

According to Fig. 5, in control group by increasing gestational age the number of corpus luteum decreases but approximately in experimental groups of 9 and 16 days of gestation number of corpus luteums is equal.

Discussion

Histological changes in the ovaries of pregnant mice that had contact with *T. gondii*, already has not been reported. In the present study, mice were infected vaginally with *T. gondii*. Our results showed that *T. gondii* could alter ovarian follicular growth and development in mice. In accordance with our results, during pregnancy significant increase in the number of atretic follicles could be due to infection with *Toxoplasma*.

In the first stage of embryonic development, increase in follicular atresia is caused by cytotoxicity process. If steroid concentrations increase in infected mice, it may lead to physiological imbalances in Hypophysial-Hypothalamic axis of ovary, which eventually inhibit the secretion of GnRH, LH and FSH. These hormones are necessary for induction of ovarian steroid synthesis. Probably, increase in steroid synthesis leads to hypertrophy of granulosa and thecal cells, physiological and morphological changes in the follicle and eventually it leads to apoptosis (20-22). Accordance to our results, significant differences were observed between corpus luteum number in experimental and control groups. The corpus luteum is a transient endocrine organ. Its main function is secreting of progesterone, which is necessary to continue the pregnancy. After ovulation, progesterone secretion from the remains of the follicle begins immediately. The follicular cells just like rays are drawn from the center to the perimeter and begin to proliferation, differentiation and angiogenesis that is like no other tissue is the body (23). The reaction of the body against toxoplasmosis can lead to increases of macrophages. Macrophages produced in a thecal layer of

follicles are growing accumulation. It seems that the macrophages play a role in follicular growth and ovulation and contribution in vascular homeostasis (24-26). Macrophages suddenly after ovulation start migrating toward the growing corpus luteum in humans, mice and rats (27-28). These cells affect steroidogenesis of corpus luteums' cells and play an important role in tissue repair after luteal regression (29-30). During each step of follicular phase, atretic changes may happen in each cell follicle. Moreover, cell death may be stimulated in some certain neighboring cell after initiating apoptosis in granulosa cells (24). The amount of apoptosis in human granulosa cells will increase after ovulation stimulation (25). The present data findings approved increased intercellular space in various areas of the corpus luteum in ovarian induction group. It seems that ovarian stimulation acts through reduction of intercellular adhesions and results in intercellular space formation. Finally, it will lead to increase in apoptosis induction rate in corpus luteum cells.

“Cell adhesions and interactions in the granulosa cells are effective in cell signaling, intercellular substrates transfer and hemostasis maintenance that finally increased intercellular space in the granulosa cells and leads to deficiency in proliferation and maturation” (26, 28). Probably, in toxoplasmosis infection macrophages are increased in uterus and ovary of host. We observe in this study that increase in ovarian macrophages may accelerate the luteal regression process and reduces the size of the corpus luteum.

Conclusion

Toxoplasmosis infection could be due to histological changes in ovaries of NMRI mice. The parasite alters ovarian follicular growth and development in mice. In addition, it alters number of all follicles (primary and secondary follicle, atretic primary and secondary follicles) and corpus luteum in ovaries of mice.

Acknowledgements

The authors would like to appreciate the Research Deputy of Arak University of Medical Sciences for financial support of this research (project number 607). The authors would like to thank Mr. Ahmad Khakbazan for the English edition. The authors declare that there is no conflict of interest.

References

- Dubey J. Toxoplasmosis—a waterborne zoonosis. *Vet Parasitol.* 2004;126:57-72.
- Dubey J. The history of *Toxoplasma gondii*—the first 100 years. *J Eukaryot Microbiol.* 2008;55:467-75.
- Sawardekar KP. Profile of major congenital malformations at nizwa hospital, oman: 10 year review. *J Paediatrics Child H.* 2005;41:323-30.
- Klein S. Hormonal and immunological mechanisms mediating sex differences in parasite infection. *Parasite Immunol.* 2004;26:247-64.
- Care AS, Diener KR, Jasper MJ, Brown HM, Ingman WV, Robertson SA. Macrophages regulate corpus luteum development during embryo implantation in mice. *J Clin Invest.* 2013;123:3472-87.
- Gatkowska J, Wieczorek M, Dziadek B, Dzitko K, Dlugonska H. Sex-dependent neurotransmitter level changes in brains of *Toxoplasma gondii* infected mice. *Exp Parasitol.* 2013;133:1-7.
- Antonios SN, Ismail HI, Essa T. Hypothalamic origin of reproductive failure in chronic experimental toxoplasmosis. *J Egypt Soc Parasitol.* 2000;30:593-9.
- Stahl W, Dias JA, Turek G. Hypothalamic-adenohypophyseal origin of reproductive failure in mice following chronic infection with *Toxoplasma gondii*. *Proc Soc Exp Biol Med.* 1985;178:246-9.
- Stahl W, Kaneda Y, Noguchi T. Reproductive failure in mice chronically infected with *Toxoplasma gondii*. *Parasitol Res.* 1994;80:22-8.
- Flegr J, Lindová J, Kodým P. Sex-dependent toxoplasmosis-associated differences in testosterone concentration in humans. *Parasitology.* 2008;135:427-31.
- Fux B, Ferreira A, Cassali G, Tafuri WL, Vitor RW. Experimental toxoplasmosis in balb/c mice. Prevention of vertical disease transmission by treatment and reproductive failure in chronic infection. *Mem Inst Oswaldo Cruz.* 2000;95:121-6.
- Coutinho LB, Gomes AO, Araújo ECB, Barenco PVC, Santos JL, Caixeta DR, Silva DAO, Cunha-Júnior JP, Ferro EAV, Silva NM. The impaired pregnancy outcome in murine congenital toxoplasmosis is associated with a pro-inflammatory immune response, but not correlated with decidual inducible nitric oxide synthase expression. *Int J Parasitol.* 2012;42:341-52.
- Fallah E, Navazesh R, Majidi J, Kushavar H, Mahdipourzareh N. An epidemiological study of *Toxoplasma* infection among high- school girls in jolfa. *J Reprod Infertil.* 2005;6:261-70.
- Fallah M, Rabiee S, Matini M, Taherkhani H. Seroepidemiology of toxoplasmosis in primigravida women in hamadan, islamic republic of iran, 2004. *East Mediterr Health J.* 2008;14:163-71.
- Bayat PD, Eslamirad Z, Shojaee S. Toxoplasmosis: Experimental vaginal infection in NMRI mice and its effect on uterin, placenta and fetus tissues. *Iran Red Crescent Med J.* 2013;15:595-9.
- Fischer AH, Jacobson KA, Rose J, Zeller R. Hematoxylin and eosin staining of tissue and cell sections. *CSH Protoc.* 2008;2008:pdb prot4986.
- Jolly PD, Smith PR, Heath DA, Hudson NL, Lun S, Still LA, Watts CH, McNatty KP. Morphological evidence of apoptosis and the prevalence of apoptotic versus mitotic cells in the membrana granulosa of ovarian follicles during spontaneous and induced atresia in ewes. *Biol Reprod.* 1997;56:837-46.
- Fortune JE. The early stages of follicular development: Activation of primordial follicles and growth of preantral follicles. *Anim Reprod Sci.* 2003;78:135-63.
- Quirk SM, Cowan RG, Harman RM, Hu CL, Porter DA. Ovarian follicular growth and atresia: The relationship between cell proliferation and survival. *J Anim Sci.* 2004;82 E-Suppl:E40-52.

20. Bernal AB, Vickers MH, Hampton MB, Poynton RA, Sloboda DM. Maternal undernutrition significantly impacts ovarian follicle number and increases ovarian oxidative stress in adult rat offspring. *PLoS One*. 2010;5(12):e15558.
21. Johnson GA, Burghardt RC, Joyce MM, Spencer TE, Bazer FW, Pfarrer C, Gray CA. Osteopontin expression in uterine stroma indicates a decidualization-like differentiation during ovine pregnancy. *Biol Reprod*. 2003;68:1951-8.
22. Miller KP, Gupta RK, Greenfeld CR, Babus JK, Flaws JA. Methoxychlor directly affects ovarian antral follicle growth and atresia through bcl-2-and bax-mediated pathways. *Toxicol Sci*. 2005;88:213-21.
23. Robertson SA. Regulatory t cells in the corpus luteum—new players in fertility control? *Biol Reprod*. 2012;86:26, 21-4.
24. Wu R, Van der Hoek KH, Ryan NK, Norman RJ, Robker RL. Macrophage contributions to ovarian function. *Hum Reprod Update*. 2004;10:119-33.
25. Van der Hoek KH, Maddocks S, Woodhouse CM, van Rooijen N, Robertson SA, Norman RJ. Intrabursal injection of clodronate liposomes causes macrophage depletion and inhibits ovulation in the mouse ovary. *Biol Reprod*. 2000;62:1059-66.
26. Turner EC, Hughes J, Wilson H, Clay M, Mylonas KJ, Kipari T, Duncan WC, Fraser HM. Conditional ablation of macrophages disrupts ovarian vasculature. *Reproduction*. 2011;141:821-31.
27. Brannstrom M, Pascoe V, Norman R, McClure N. Localization of leukocyte subsets in the follicle wall and in the corpus luteum throughout the human menstrual cycle. *Fertil Steril*. 1994;61:488-95.
28. Herbison AE, Porteous R, Pape J-R, Mora JM, Hurst PR. Gonadotropin-releasing hormone neuron requirements for puberty, ovulation, and fertility. *Endocrinology*. 2008;149:597-604.
29. Nelson S, McLean M, Jayatilak P, Gibori G. Isolation, characterization, and culture of cell subpopulations forming the pregnant rat corpus luteum. *Endocrinology*. 1992;130:954-66.
30. Terranova P, Rice VM. Review: Cytokine involvement in ovarian processes. *Am J Reprod Immunol*. 1997;37:50-63.