



Tehran University of Medical
Sciences Publication
<http://tums.ac.ir>

Iran J Parasitol

Open access Journal at
<http://ijpa.tums.ac.ir>



Iranian Society of Parasitology
<http://isp.tums.ac.ir>

Case Report

First Report of Nasal Myiasis Caused by *Lucilia sericata* in the Pediatric Age Group from Tehran, Iran

Shirin Sayyahfar ¹, Ramin Zare Mahmoudabadi ², Soheila Mahdavynia ³,
Abdoulreza Esteghamati ¹, Borna Salemi ⁴, *Khadijeh Khanaliha ¹

1. Research Center of Pediatric Infectious Diseases, Institute of Immunology and Infectious Diseases, Iran University of Medical Sciences, Tehran, Iran
2. Department of Pediatrics, Firoozabadi Hospital, Iran University of Medical Sciences, Tehran, Iran
3. Department of Pediatric Nephrology, Firoozabadi Hospital, Iran University of Medical Sciences, Tehran, Iran
4. Student Research Committee, School of Medicine, Iran University of Medical Sciences, Tehran, Iran

Received 22 Aug 2021
Accepted 11 Nov 2021

Keywords:

Myiasis;
Lucilia sericata;
Pediatric;
Nasal;
Iran

***Correspondence**

Email:
khanaliha.kh@iums.ac.ir

Abstract

Myiasis is an infestation caused by dipterous larvae. Nosocomial myiasis usually occurs in bedridden patients. Herein, we report a nasal myiasis in a 12-year-old female with cerebral palsy (CP) from Tehran, Iran and provide morphological identification of *Lucilia sericata* as the causative agent. The infection was identified 10 days after the hospital admission. It can be categorized as a nosocomial infection. As far as we are aware, this is the first report of nasal myiasis in the pediatric age group from Tehran, Iran.

Introduction

Myiasis is an infestation caused by dipterous larvae. Different species of dipterans are identified as the

etiology of this infection in humans and animals (1). Dipterans that cause myiasis can be divided in three groups ; specific, semi-specific,



Copyright © 2022 Sayyahfar et al. Published by Tehran University of Medical Sciences.
This work is licensed under a Creative Commons Attribution-NonCommercial 4.0 International license.
(<https://creativecommons.org/licenses/by-nc/4.0/>). Non-commercial uses of the work are permitted, provided the original work is properly cited

and accidental and the disease caused by them is identified as obligatory, facultative, and accidental, respectively (1).

Facultative myiasis normally develops in vegetable materials and dead tissue; however, it sometimes involves the live tissues of animals and humans (1). Female flies are attracted by the discharge of inflamed regions, eye, nose and wounds and lay eggs in these areas (2).

Myiasis is usually found in overcrowding areas with substandard hygienic conditions; however, it may also be reported from nursing homes and hospitals as a nosocomial infection (3). The most common infested sites are the opening orifices of the body (e.g., nose, eye, ear, anus, vagina and damaged skin).

A few cases of human myiasis producing facultative myiasis have been reported from Iran (4-6) and different countries (2, 7). The most important family causing myiasis is *Calliphoridae* family that includes *Calliphora*, *Lucilia*, *Chrysomyia* and *Cochliomyia* genera (8, 9). *Lucilia* sp. has a worldwide distribution and causes myiasis in humans and herbivorous animals (10).

Nasal myiasis from *Lucilia* spp. has been reported in some previous studies (8, 11, 12). Here, we report a case of human, nasal myiasis from Tehran, Iran and define morphological identification of *L. sericata* as the etiology of this disease.

Case report

A 12-year-old female as a known case of cerebral palsy (CP) was admitted to Intensive Care Unit (ICU) of Firoozabadi Hospital, Iran University of Medical Sciences, Tehran, Iran with decreased level of consciousness. The patient suffered from sepsis, respiratory distress, gastrointestinal bleeding (GIB) and hypoglycemia. The noninvasive ventilation (NIV) was used to treat respiratory failure, wide spectrum antibiotics and hypertonic glucose were started, and the general condition was improved gradually. On the 10th day of staying in ICU when the patient was under

fixed NIV, a few [2-3] white seemingly, with about 9.5 mm length worms escaped from the patient's right nose for three consecutive days.

Ethic consideration

Ethical approval for the study and informed consent forms were approved by ethics committee of Institute of Immunology and Infectious Diseases, Iran University of Medical Sciences. The written informed consent was taken from the patient by legally authorized representative.

Laboratory data indicated pancytopenia, positive the blood and the sample obtained from the mini Bronchoalveolar lavage (BAL) culture were positive with *Klebsiella pneumoniae*.

The larva was collected and preserved with 70% ethyl alcohol and transferred to the parasitology laboratory in Research Center of Pediatric Infectious Diseases for identification. At first, the size of the larva was measured, and then the fixed larva was sliced longitudinally and vertically for more assessment of the morphological details. It was immersed in 10% aqueous KOH and then mounted with polyvinyl alcohol (2), and finally observed under a light microscope. Morphological assessment of the larva was performed based on keys, provided by James (13).

The maggot was a third-instar larva, with the length and width of 9.5 mm and 1.5 mm. The body was almost tapered caudally and its color was white. The cylindrical body consisted of 12 segments. Although, the color of the larva was white, the internal organs were red-brown. The body of larvae in necrophagous *Calliphoridae* family had the special pattern for Calyptrata, three thoracic segments and seven abdominal segments (Fig. 1, A, B).

The spine band was observed at the back ends of segments including numerous tiny single-pointed spines (Fig. 2, A). The larva pseudocephalon had 2 antennae with a sensory papilla on each antenna, and also 2 characteristic hooks were identified in the buccal cavity (Fig. 2, B)

Anterior spiracles position located at the anterolateral part of the body and were fan-shaped or finger-like shaped with 8 finger lobes. Posterior spiracles including three straight slits were set at the posterior end of the body, and were round with a button, that were closed by a peritremal ring without any gap (Fig.3, A, B).

Furthermore, *L. sericata* can be identified from *L. cuprina* instar that is an identical genus

regarding that *L. sericata* larva has 7-10 finger lobes in the anterior spiracle in comparison with 4-5 lobes in *L. cuprina* that possesses a complete peritreme (14).

Finally the larva was identified as the third instar of *L. sericata* (Diptera: Calliphoridae) using morphological method. The patient was treated with a single dose of Ivermectin (3 mg) that was repeated once after 2 weeks. No other worm was detected after treatment.

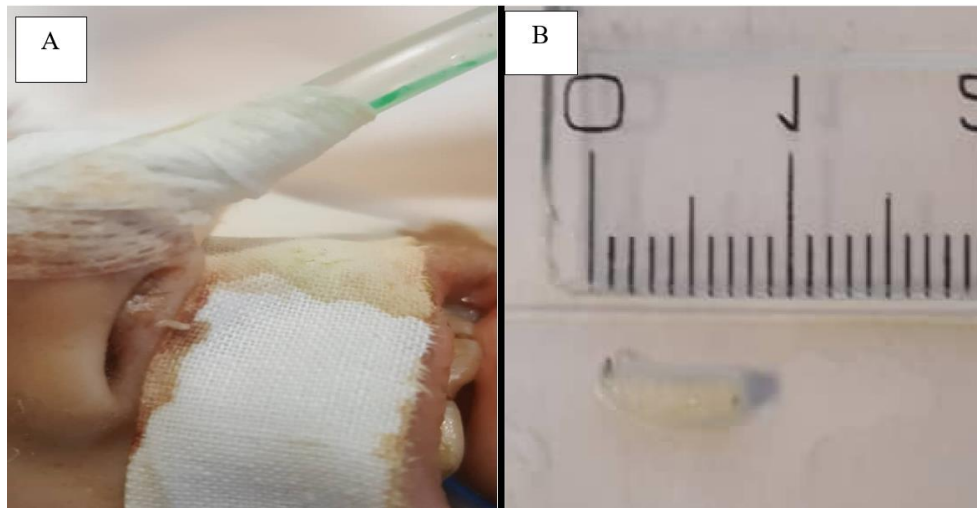


Fig. 1: (A): Third instar larvae of *L. sericata* escaped from nose. (B): Views of third instar larvae.

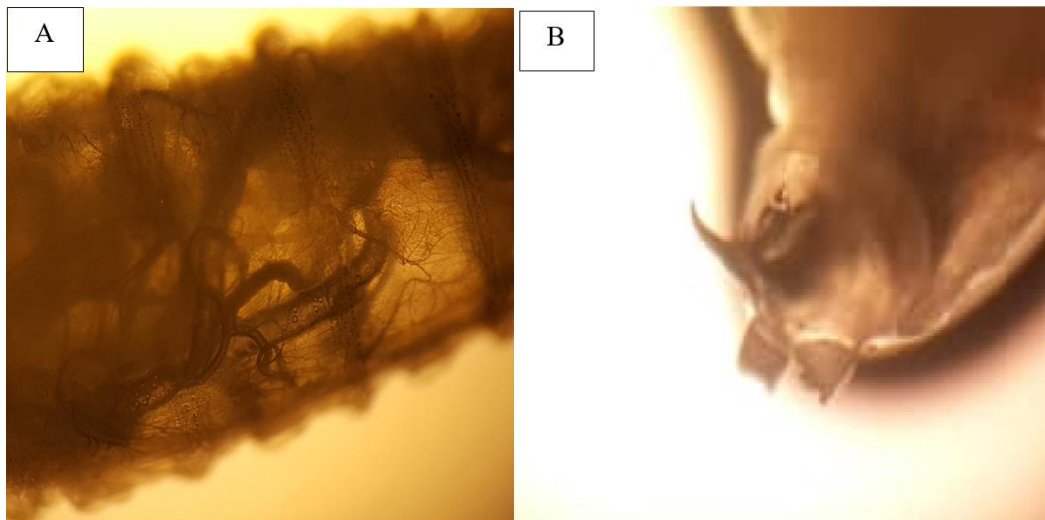


Fig. 2: (A): Pointed bands of spines. (B): Larva pseudocephalon consists of 2 antennae and 2 hooks

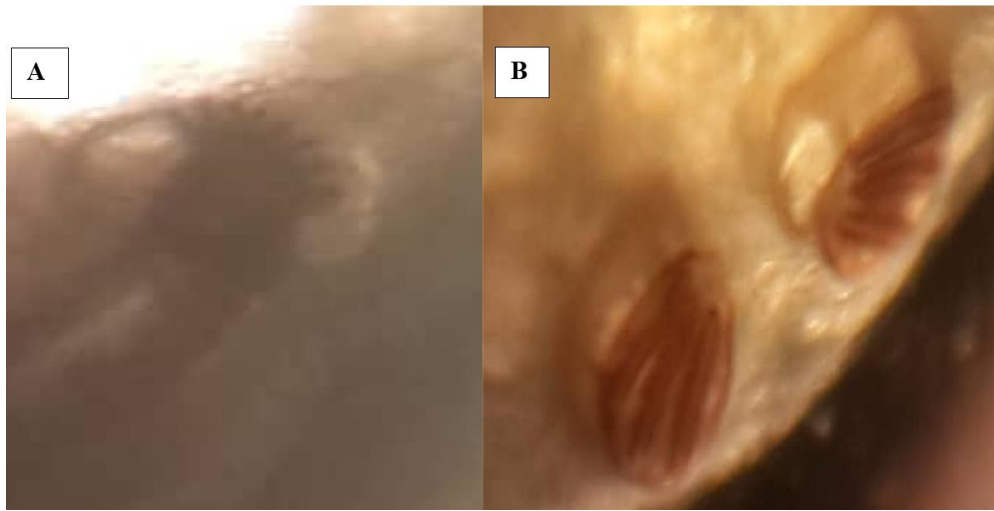


Fig. 3: (A): Anterior spiracle with 8 lobes. (B): Posterior spiracle with button. (Original Pictures)

Discussion

Nasal myiasis is due to the placing of the fly larva in the human nostrils. The prevalence of myiasis in developing countries and tropical areas is considerable. Nosocomial myiasis usually occurs in bedridden patients (15). The nosocomial myiasis infections rate is about 4% and mortality rate is 1.3% in Iran (16).

Dipterans are usually identified according to morphological features, and morphological differences in developmental stages including egg, larvae, and pupae needs precise consideration (2).

Myiasis can progress into malignant situations with some species (17). Furthermore, screwworms, like *Cochliomyia hominivorax* and *Chrysomya bezziana*, can cause septicemia, secondary infections, and if untreated, result in host death (18), so diagnosis of species is important.

In the present study, the maggot with typical morphological features of *L. sericata* was identified according to the characteristic features with identification keys and diagnosed as nasal myiasis in a general hospital in Tehran.

In a study, the fauna of medically important flies causing myiasis including Calliphoridae and Sarcophagidae was evaluated in

Tehran, Iran. Out of 856 captured flies, 643 were from Calliphoridae family and 213 belonged to Sarcophagidae. Three species of *Lucilia* including, *L. caesar*, *L. sericata* and *L. richardsi* were reported. Moreover, *L. richardsi* was reported for the first time (9).

Nasal nosocomial myiasis due to *L. sericata* has been reported from Iran (15), Kuwait (11), and Korea (12). A few cases of adult nasal nosocomial myiasis caused by *L. sericata* has been reported from different provinces of Iran, such as a 69-year-old man presented with dyspnea from Babol, (15) a 35-year-old patient with gastric cancer and respiratory distress from Ahwaz (8), a fatal case of nosocomial myiasis in a 54-year-old female after coronary artery bypass grafting in Tehran (19), and a nasal nosocomial myiasis caused by *Chrysomya bezziana* in a 74 – year-old woman with dyspnea from Gonabad (4). However, as far as we know, our case is the first report of *L. sericata* myiasis from pediatric age group of Tehran, Iran.

Infestation of ocular tissue by *L. sericata* in a patient with retina vascular tumor, from Bijar City of Kurdistan (20) and intestinal myiasis caused by *L. illustris* have been reported (21). A gingival myiasis caused by *Wohlfartia magnifica* in a pediatric mental retarded boy was

reported from Bardestan village located in Bushehr Province, south of Iran (22).

Averagely, the minimum duration between egg laying to completion of the second instar stage of *L. sericata* is almost 50 hours at 29 °C and totally, three days take time to the end of the larval feeding stage (11).

Regarding to detection of the larva after ten days admission in ICU it can be concluded that nasal myiasis of our patient occurred in the hospital and could be considered as a nosocomial infestation.

Conclusion

A case of nasal myiasis caused by *L. sericata* was identified in this study. The clinicians should be aware and consider myiasis as a kind of nosocomial infection.

Acknowledgments

This study was self-funded and was done in Research Center of Pediatric Infectious Diseases, Iran University of Medical Sciences in Tehran, Iran.

Conflicts of interest

The authors declare there are no conflicts of interest

References

1. Patton WS. Notes on the myiasis-producing Diptera of man and animals. Bull Entomol Res. 1921;12(3):239-61.
2. Choe S, Lee D, Park H, et al. Canine wound myiasis caused by *Lucilia sericata* (Diptera: Calliphoridae) in Korea. Korean J Parasitol. 2016;54(5):667-671.
3. Thompson Jr J, Knutson L, GULP O. Larva of *Scenopinus* sp.(diptera: scenopinidae) causing human urogenital myiasis? Mayo Clin Proc. 1970; 45(8):597-601.
4. Mircheraghi SF, Mircheraghi SF, Riabi HRA, et al. Nasal nosocomial myiasis infection caused by *Chrysomya bezziana* (Diptera: Calliphoridae) following the septicemia: a case report. Iran J Parasitol. 2016;11(2):284.
5. Najjari M, Shafiei R, Fakoorziba MR. Nosocomial myiasis with *Lucilia sericata* (Diptera: Calliphoridae) in an ICU patient in Mashhad, Northeastern of Iran. Arch Iran Med. 2014; 17(7):523-5.
6. Faramarzi A, Rasekhi A, Kalantari M, et al . *Chrysomya bezziana* as a causative agent of human myiasis in Fars Province, southern Iran. Iran J Arthropod Borne Dis. 2009;3(1):60-3.
7. Manfrim AM, Cury A, Demeneghi P, et al . Nasal myiasis: case report and literature review. Int Arch Otorhinolaryngol. 2007;11(1):74-9.
8. Salmanzadeh S, Rahdar M, Maraghi S, et al. Nasal Myiasis: A Case Report. Iran J Public Health 2018; 47(9):1419-1423.
9. Khoobdel M, Jonaidi N, Rashti MS. Blowfly and flesh fly (Diptera: Cyclorrhpha) fauna in Tehran, Iran. J Entomol. 2008;5(3):185-192.
10. Sharma H, Dayal D, Agrawal S. Nasal myiasis: review of 10 years experience. J Laryngol Otol. 1989;103(5):489-91.
11. Hira PR, Assad RM, Okasha G, et al. Myiasis in Kuwait: nosocomial infections caused by *Lucilia sericata* and *Megaselia scalaris*. Am J Trop Med Hyg. 2004;70(4):386-9.
12. Kim J-S, Seo P-W, Kim J-W, et al. A nasal myiasis in a 76-year-old female in Korea. Korean J Parasitol. 2009;47(4):405-407.
13. James MT. The flies that cause myiasis in man: US Department of Agriculture; 1947.
14. Walker AR. Arthropods of humans and domestic animals: a guide to preliminary identification: Springer Science & Business Media; 1994.
15. Youssefi M, Rahimi M, Marhaba Z. Occurrence of nasal nosocomial myiasis by *Lucilia sericata* (Diptera: Calliphoridae) in north of Iran. Iran J Parasitol. 2012;7(1):104-8.
16. Alizadeh M, Mowlavi G, Kargar F, et al . A review of myiasis in Iran and a new nosocomial case from tehran, Iran. J Arthropod Borne Dis. 2014;8(2):124-131.
17. Singh T, Rana D. Urogenital myiasis caused by *Megaselia scalaris* (Diptera: Phoridae): a case report. J Med Entomol. 1989;26(3):228-9.
18. Scholl PJ, Colwell DD, Cepeda-Palacios R. Myiasis (Muscoidea, Oestroidea). Med Vet Entomol: Elsevier; 2019. p. 383-419.

19. Mowlavi G, Nateghpour M, Teimoori S, et al . Fatal nosocomial myiasis caused by *Lucilia sericata*. J Hosp Infect. 2011;78(4):338-9.
20. Norouzi R, Manochehri A, Zarrin S. External ophthalmomyiasis caused by *Lucilia sericata* (Diptera: Chalcididae) larva. Iran J Parasitol. 2017;12(3):466-469.
21. Norouzi R, Manochehri A. Case report of human intestinal myiasis caused by *Lucilia illustris*. Arch Clin Infect Dis. 2017;12(1): e36306.
22. Mohammadzadeh T, Hadadzadeh H, Esfandiari F, et al. A case of gingival myiasis caused by *Wohlfahrtia magnifica*. Iran J Arthropod Borne Dis.2008; 2(1): 53-6.