



Tehran University of Medical  
Sciences Publication  
<http://tums.ac.ir>

## Iran J Parasitol

Open access Journal at  
<http://ijpa.tums.ac.ir>



Iranian Society of Parasitology  
<http://isp.tums.ac.ir>

### Original Article

## Molecular Assay Proves the Presence of *Theileria annulata* Infection in Camels in Al-Diwaniyah Province, Iraq

\*Noaman N. A'aiz<sup>1</sup>, Hayder N. Ayyez<sup>2</sup>, Ahmed J. Neamah<sup>2</sup>

1. Department of Microbiology and Parasitology, College of Veterinary Medicine, University of Al-Qadisiyah, Al-Qadisiyah, Iraq
2. Department of Zoonotic Diseases, College of Veterinary Medicine, University of Al-Qadisiyah, Al-Qadisiyah, Iraq

Received 13 Jul 2020  
Accepted 20 Oct 2020

#### Keywords:

*Theileria*;  
*Camelensis*;  
*Dromedarii*;  
*Annulata*;  
Camel

#### \*Correspondence

Email:  
[noaman.aaz@qu.edu.iq](mailto:noaman.aaz@qu.edu.iq)

#### Abstract

**Background:** *Theileria camelensis* and *T. dromedarii* are parasitic protozoans reported by several studies as specific species that infect the one-humped camel (*Camelus dromedarius*). However, other findings casted significant doubts on the true identity of the causative species of theileriosis in camels. Therefore, the present study was conducted to investigate of *T. camelensis* and *T. dromedarii* in one humped camels in Iraq during Apr-Oct 2017.

**Methods:** Blood samples for DNA extraction were obtained from 181 slaughtered camels. Molecular investigation was performed following the amplification of 18S rRNA gene by conventional PCR technique. DNA sequencing was then utilized only for the positive samples to confirm the infection with the *Theileria* species.

**Results:** Nine (4.97%) out of 181 examined samples showed a positive result to infection with *Theileria* spp., and all these appeared as a *T. annulata* when subjected to DNA amplification and sequencing techniques. There was a complete absence of any new sequence outside the known species.

**Conclusion:** Most of *Theileria* infection in camels in the study area is caused by *T. annulata* and no other causative agents like *T. camelensis* or *T. dromedarii*.

### Introduction

Over 27 million of one-humped and two-humped camels have been recorded in the world (1). Camels con-

sidered a very important investment in the desert areas. They have been used since the



Copyright © 2021 A'aiz et al. Published by Tehran University of Medical Sciences.  
This work is licensed under a Creative Commons Attribution-NonCommercial 4.0 International license  
(<https://creativecommons.org/licenses/by-nc/4.0/>). Non-commercial uses of the work are permitted, provided the original work is properly cited.

old times for transportation and as a good source of meat, milk, and wool (2).

Although, camels are susceptible to wide variety of infectious diseases, their physical ability and the unique adaptive physiological measures of their bodies on confronting the harsh environment of arid areas make them irreplaceable animals to the survival of the mankind (3,4).

Many parasitic infections are known to infect camels causing anemia, wasting and death in severe cases (5). Theileriosis in camel was firstly reported in Russia that gave it the name *Theileria camelensis* (6). Theileriosis is a tick-born protozoan disease associated with *Theileria* spp. (Piroplasmida, Theileridae) in farm as well as in wild and captive ungulates. It's considered as one of the most important diseases of farm animals that could induce a variety of clinical signs ranging from mild to fatal conditions depending, in some cases, on the species of the protozoan, and the area of distribution (7, 8). In India, (9) reported another species *T. dromedarii* that can infect camels as well. Since then, *T. camelensis* and *T. dromedarii* have been recorded in Turkmenistan, Egypt, Somalia, India and Saudi Arabia (9, 10). Little is known about these two species, and since only erythrocytic piroplasm stages have been observed, so their classification is not clear yet (11).

Generally, camels tend to not show any clinical signs of diseases and most of the time appears healthy in spite of *Theileria* infection (12, 13). *Hyalomma dromedarii* ticks are the main vector for *Theileria* transmission among camels and there are different developmental stages of protozoan inside this vector had been recorded (13).

Most diagnostic and most widely method used in detection of *T. camelensis* and *T. dromedarii* is still dependent upon direct blood picture microscopic examination (6, 10, 12, 13). Other studies utilized the molecular detection approach to confirm infection with the pathogen (14-16). However, most molecular studies have failed to detect the specific species that

could infect camels (*T. camelensis* and *T. dromedarii*).

Thus, the aim of this study was to investigate the possibility of detecting these two species of *Theileria* using the molecular and sequencing methods.

## Materials and Methods

This study was conducted during Apr-Oct 2017 in Al-Diwaniyah Province, located in central Iraq, between latitude 31.17 and 32.24°N, and longitude 44.24 and 45.49°E, where there is a lot of camel breeding. Whole blood was collected from jugular vein of 181 slaughtered camels of both sexes and different ages, where they brought to the abattoir from different regions of the province.

The samples were kept into tubes with anticoagulant (EDTA), with the information of age and sex were fixed on the tubes, and then transported to the laboratory of parasitology in College of Veterinary Medicine - University of Al-Qadisiyah for the laboratory examination.

DNA extraction was done for all samples using DNA extraction kit (Geneaid, USA), based on manufacturer's instructions. The yielded DNAs were stored at -20 °C.

Reference primers were used based on the *18S rRNA gene* sequence of *Theileria* and *Babesia* spp. The forward strand primer 5'-GCATTCGTATTAACTGTCAGAGG-3' and reverse strand primer 5'-GATAAGGTTACAAAACCTCCCTAG-3' (17). Primers were provided by Bioneer Company/Korea.

Detection of the protozoan parasite, a conventional PCR was prepared by adding of 50 µl including: 5µl of DNA template, 2.5µl (10Pmol) of each forward and reverse primers and 40µl deionized sterile distilled water (Bioneer/Korea) to each tube of Accupower PCR PreMix kit (Bioneer/Korea) that which contain the PCR reaction requirements (Taq

DNA polymerase, dNTPs, Tris-HCl pH: 9.0, KCl, MgCl<sub>2</sub>, Stabilizer and tracking dye).

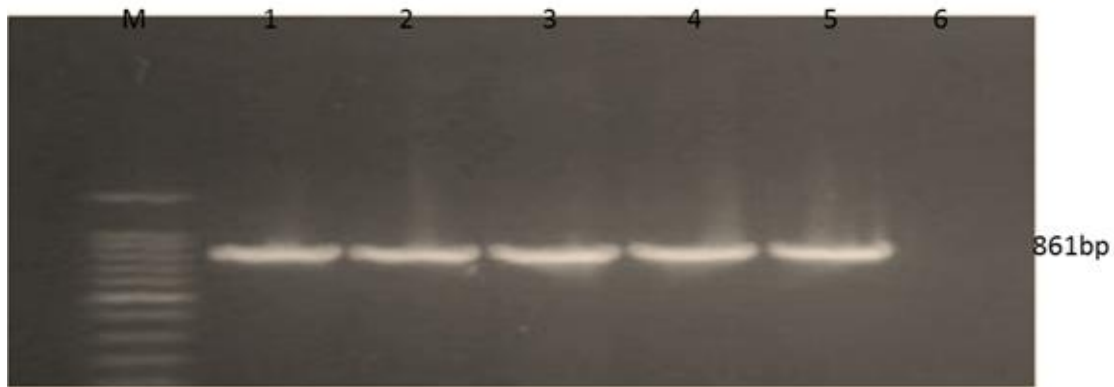
The amplification was performed in an automated thermocycler (Mltigene/China) by following the program: Initial denaturation at 94 °C for 5 min followed by 30 cycles of denaturation at 94 °C for 30 sec, annealing at 59 °C for 60 sec and elongation at 72 °C for 60 sec, then final extension at 72 °C for 5 min and holding at 4 °C. The expected PCR products (861bp) were electrophoresed through a 1.5% agarose gel.

DNA sequencing was performed for positive PCR products by AB sequencing system

(Bioneer/Korea). The phylogenetic analysis was then aligned on NCBI-blast Alignment identification and Unweight Pair Group Method with Arithmetic Mean tree (UPGMA tree).

## Results

Nine (4.97%) females (3 to 10 yr) out of the total examined camels (181) have shown a positive result by PCR technique when amplified the 861bp product, which refers to infection with *Theileria* / *Babesia* spp. (Fig. 1).

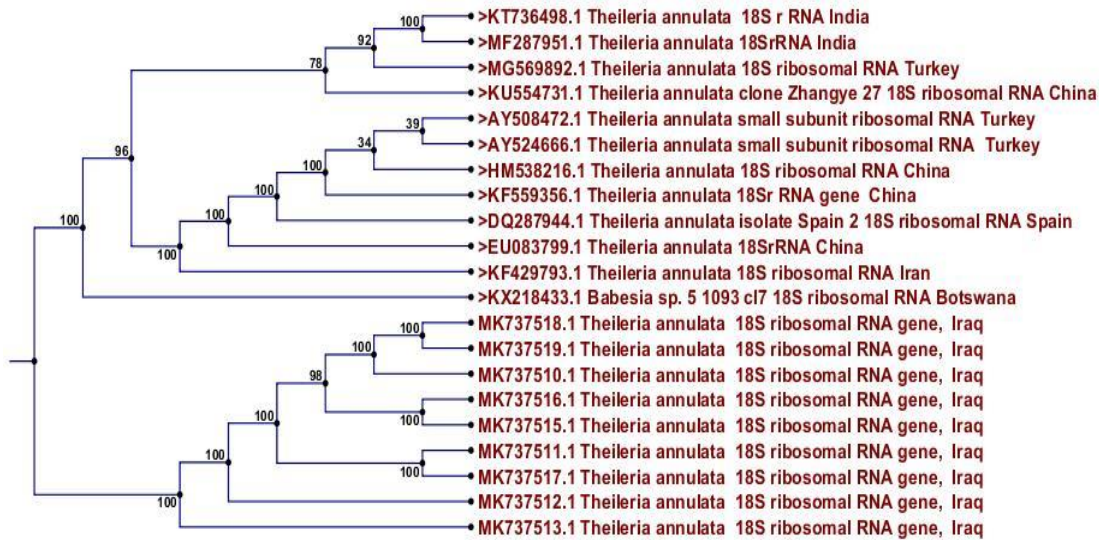


**Fig. 1:** Gel agarose electrophoresis of amplified camels DNA using *Theileria/Babesia 18S rRNA* gene specific primers. M: 100 bp DNA size marker, lanes 1 to 5 positive samples (861bp); lane 6 negative sample


The phylogenetic analysis of the positive samples based on the partial sequence of *18S rRNA gene*, in which the evolutionary distances were computed using the Maximum Composite Likelihood method by phylogenetic tree UPGMA method (CLC6.7.1 version), revealed that all analyzed samples isolate (no.1- no.9) showed a close relation to NCBI-Blast *Theileria annulata* under several accession numbers (MF287917.1, KT736498.1, KF559356.1, EU083799.1, AY524666.1, HM538216.1, AY508472.1, DQ287944.1, MG569892.1, KF429793.1 and KU554731.1), whereas the

sequence identity matrix and query cover showed 97%-100% homology between *T. annulata 18S rRNA* sequence of Iraq strain and of other strains that present in the NCBI from several parts of the world. The nucleotide sequences of *18S rRNA gene* of *T. annulata* strains were submitted in the GenBank and were given an accession numbers; MK737510.1, MK737512.1, MK737514.1, MK737515.1, MK737516.1, MK737517.1, MK737513.1, MK737519.1 and MK737518.1 (Fig. 2 and 3).





**Fig. 2:** UPGMA method analysis of the *18S rRNA gene* of the *Theileria annulata* GenBank database. Numbers above the branch demonstrate bootstrap support from 1000 replications. The tree was created using the CLC6.7.1 package, the KX218433.1 (*Babesia* spp.) was used as an out group



**Fig. 3:** Partial sequence of *18S rRNA* represent alignment among local and global *T. annulata* sequences

## Discussion

*Theileriosis* is a haemoprotozoan parasitic disease. The infective agent infects several domestic animals (18).

In camels there are two species known that cause the disease, *T. camelensis* and *T. dromedarii*, were firstly reported in Turkistan and India (6, 19). Other studies refer to these two species (particularly *T. camelensis*) in Egypt (12, 13) and

in Saudi Arabia (10) depending upon the morphological description of the parasite through microscopically examination of stained blood films.

The exact speciation of *Theileria* protozoa is still highly in doubt (20), therefore recent studies recommended examining the camel's theileria species by adopting the specific molecular methods to confirm infection (10,15).

Thus, the current study applied the molecular detection examination, which revealed that

9 (4.97%) out of 181 examined camels suffered from *Theileria* infection, and all positive cases were identified as *T. annulata*. The current results are in agreement with (16) who identified *T. annulata* species in one PCR positive sample. Other molecular studies which investigated the camel's theileriosis referred to infection with *Theileria* spp. and no one confirmed the infection with *T. camelensis* or *T. dromedarii* (16,21).

According to the obtained findings here and other molecular studies, there was a misdiagnosis of the disease in the presence of specific camel *Theileria* species (*T. camelensis* or *T. dromedarii*), which highly suggested infection with *T. annulata* species.

A previous study (18), questioned the validity of these species. The previous authors did not clarify the morphological characters or the incidence of the parasite and the species of the investigated camel. On the other hand, he had described the morphology of *T. camelensis* as a rod and ring shape forms within the erythrocytes measured 1.3-2.6  $\mu\text{m}$  x 0.5-1  $\mu\text{m}$  and 0.5-1.3  $\mu\text{m}$  size respectively. The description is interfered with the description of *T. annulata* (18). Moreover, there were no significant abnormalities in parasitized camels, which may be evidence for infection with non-host specificity species (9, 12, 13, 18).

On other side, the tick vector which responsible for transferring the *Theileria* infection to the camel was identified as *Hyalomma dromedarii* (13,20,22). This species was mentioned as one of different tick vectors of *T. annulata* transporter (18), which makes it an important factor in transmitting this protozoan infection from camels to other farm animals, especially to naive and susceptible cattle, which are the specific host of *T. annulata* (23, 24).

In respect to *T. dromedarii* there were poor studies related to this species, and certain study hinted to that the *T. camelensis* referred to it as *T. dromedarii* (9).

According to our results and other molecular studies, there was no indication of the presence of *T. camelensis* and *T. dromedarii*, in

addition to the lack of a database for these two species in National Center for Biotechnology Information (NCBI), so a conducting of an experimental and molecular studies to prove the existence of the above species is an important issue.

## Conclusion

The findings of this study have clarified a significant doubt regarding the presence of specific *Theileria* species in camels and here we propose there are no *T. dromedarii* and *T. camelensis* infection in our studied samples and all positive specimens proved *T. annulata* infection only.

## Acknowledgments

We acknowledge all the efforts of the veterinarians at the Al-Diwaniyah city abattoir for their kind assistance in collecting the blood samples.

## Conflict of interest

The authors declare that there is no conflict of interest.

## References

1. Food and Agriculture Organization of the United Nations. FAOSTAT - Food and agriculture organization of the United Nations statistics division. Rome, Italy. 2014; <http://www.fao.org/faostat/en/>
2. Kamani J, Usman TA, Onyemaechi EG, et al. Hemoparasites of camels (*Camelus dromedarius*) in Maiduguri, Nigeria. Anim Res Int. 2008; 5: 838-839.
3. Karimi A, Rahbari S, Yousefi A. Blood parasites of camels from central regions of Iran: comparative evaluation of various detection techniques and serum protein components. J Adv Parasitol. 2015; 2: 1-4.
4. Swelum AA, Ismael AB, Khalaf AF, Abouheif MA. Clinical and laboratory findings associated

- with naturally occurring babesiosis in dromedary camels. Bull Vet Inst Pulaway. 2014; 58: 229-233.
5. Mahran OM. Some studies on Blood Parasites in Camels (*Camelus dromedarius*) at Shalatin City, Red Sea Governorate. J Eukaryot Microbiol. 1989; 36: 422-423.
  6. Yakimoff WL, Schokhor NI, Kosel-Kine PM. In Maladies animals du Turkestan russe a parasites endoglobulaires. Bull Soc Path Exot. 1917; 10, 303-305. Cited by Gatt-Rutter TE. Protozoal Diseases of Camel. Vet Bull. 1967; 37: 611-618.
  7. Mukhebi AW, Perry BD, Kruska R. Estimated economics of theileriosis control in Africa. Prev Vet Med. 1992; 12: 73-85.
  8. Radostits OM, Gay CC, Hinchcliff KW, Constable PD. Babesiosis. In: Veterinary Medicine: A textbook of the diseases of cattle, horses, sheep, pigs, and goats. 10th ed. Saunders/Elsevier. 2007: 1483-1498.
  9. Hekmatimoghaddam S, Sazmand A, Rasooli A, et al. Laboratory tests in dromedary camels naturally infected with piroplasms in Iran: Study and review of literature. Journal of Camel Practice and Research. 2012; 19: 217-221.
  10. Ismael AB, Swelum AA, Khalaf AF, Abouheif MA. Clinical, haematological and biochemical alterations associated with an outbreak of theileriosis in dromedaries (*Camelus dromedarius*) in Saudi Arabia. Pak Vet J. 2014; 34(2):209-13.
  11. Elghali A, Hassan SM. Drop-off rhythms and survival periods of *Hyalomma dromedarii* (Acari: Ixodidae) fed on camels (*Camelus dromedarius*) in the Sudan. Vet Parasitol. 2010; 170:302-306.
  12. Nassar AM. *Theileria* infection in camels (*Camelus dromedarius*) in Egypt. Vet Parasitol. 1992; 43:147-149.
  13. Hamed MI, Zaitoun AMA, El-Allawy TAA, Mourad IM. Investigation of *Theileria camelensis* in camels infested by *Hyalomma dromedarii* ticks in Upper Egypt. J Adv Vet Res. 2011;1: 4-7.
  14. Barghash SM, Hafez AA, Darwish AM, Abou El-Naga TR. Molecular Detection of Pathogens in Ticks Infesting Camels in Matrouh Governorate, Egypt. J Bacteriol Parasitol. 2016; 7(2): 259-62.
  15. Moezi V, Sarani1 A, Hashemi H, Rasekh M. Molecular study of *Theileria camelensis* and *Theileria dromedarii* strains based on sequence of 18s ribosomal DNA fragment in camels. J Fundam Appl Sci. 2016; 8(2S):399-406.
  16. Sazmand A, Eigner B, Mirzaei M, et al. Molecular Identification of Hemoprotozoan Parasites in Camels (*Camelus dromedarius*) of Iran. Iran J Parasitol. 2016; 11(4): 568-573.
  17. Jalali SM, Khaki Z, Kazemi B, Rahbari S. Molecular detection and identification of *Theileria* species by PCR-RFLP method in sheep from Ahvaz, Southern Iran. Iran J Parasitol. 2014; 9(1):99-106.
  18. Tylor AM, Coop RL, Wall RL. Veterinary parasitology. Third Edition, Blackwell publishing. 2007: P.1345-1346.
  19. Mishra AK, Sharma NN, Raghavendra Rao J. *Theileria dromedarii* N.SP. from Indian camels (*Camelus dromedarius*). Rivista di Parassitologia. 1987; 4: 99-102.
  20. Boid R, Jones TW, Luckins AG. Protozoal Diseases of Camels. Br Vet J. 1985; 141: 87-105.
  21. Abou El-Naga TR, Barghash SM. Blood Parasites in Camels (*Camelus dromedarius*) in Northern West Coast of Egypt. J Bacteriol Parasitol. 2016; 7: 258.
  22. Hoogstraal H. Notes on African Haemaphysalis ticks. III. The hyrax parasites, *H. bequaerti* sp. nov., *H. orientalis* N. and W., 1915 (new combination), and *H. cooleyi* Bedford, 1929 (Ixodoidea, Ixodidae). J Parasitol. 1956; 42:156-172.
  23. Mustafa U, Jongejan F, Morzaria SP. Note on the transmission of *Theileria annulata* by *Hyalomma* ticks in Sudan. Vet Q. 1983; 5(3): 112-113.
  24. Asadollahi1 Z, Jalali MHR, Alborzi A, Hamidinejat H. Detection of *Theileria*-like organisms in *Hyalomma* ticks (Acarina: Ixodidae) in Khuzestan, Iran. Sci Parasitol. 2018; 19(1-2):34-39.