



Tehran University of Medical  
Sciences Publication  
<http://tums.ac.ir>

## Iranian J Parasitol

Open access Journal at  
<http://ijpa.tums.ac.ir>



Iranian Society of Parasitology  
<http://isp.tums.ac.ir>

### Case Report

## Presence of Visceral Larva Migrans in the Urinary Bladder of a Woman in Khorramabad, Iran

*SE Rafiee Alavi<sup>1</sup>, \*H Nayebzadeh<sup>2</sup>*

<sup>1</sup>*Department of Pathobiology, School of Medicine, Lorestan University of Medical Sciences, Iran*

<sup>2</sup>*Department of Pathobiology, School of Veterinary Medicine, Lorestan University, Iran*

### ABSTRACT

The presence of Visceral Larva Migrans (VLM) in a patient is reported. A 57-year-old woman suffering from right upper abdominal and suprapubic pain referred into a clinic in Khorramabad, Lorestan Province, Iran. A cystoscopy was performed and biopsy was taken. The light microscopic study showed a couple of larvae as well as mononuclear inflammatory cell-infiltration. Because occurrence of VLM is potentially problem in rural areas, it is recommended that an educational program to be initiated to prevent and control VLM infection in both rural and urban people. Clinicians also should consider the clinical features of visceral larva migrans.

**Keywords:** *Visceral Larva Migrans, Toxocara, Iran*

\*Corresponding author: Tel: # 98-0661 6200109, Fax: #98-0661 6200109, E-mail: [hassannayeb@yahoo.com](mailto:hassannayeb@yahoo.com)

## Introduction

Visceral Larva Migrans (VLM) is caused by the migration of some nematodes including *Toxocara* species larvae into human body's organs (1). One of the important factors in the epidemiology of VLM is the largeness of the population of the canine in an area (2). There are four ways in which humans become infected with VLM: ingesting embryonated eggs from soil, contaminated hands, raw vegetables, and eating under cooked giblets infected with the larvae (1). The degree of the damage to the host and its signs depends on the attacked tissues (3). The disease has various clinical features (4, 5).

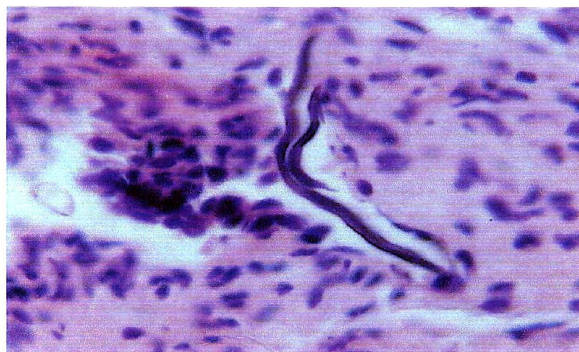
In the city of Zabol, Iran, one case of VLM (a 5 years old boy) was diagnosed by clinical signs, biochemical and hematological tests, and the result was confirmed using the serological test (6). By collecting information about factors as clinical signs and symptoms; past history, biochemical and hematological tests; Indirect Fluorescence Antibody test (IFA), and follow-up of patients, 10 human cases of VLM were diagnosed in Iran, from 1993 to 1995 (7). Seroprevalence of VLM in children (2-12 years old) living in the Mahidasht area of Kermanshah Province; in children under 10 years old in the city of Hamadan; and among the school children living in

the city of Shiraz was 8.46%; 5.3%, and 25.6%, respectively (8, 9, 10).

We report here a patient with VLM in her bladder tissue.

## Case Report

A 57-year-old woman referred to a clinic in Khorramabad with complains of pain in her right upper abdominal and suprapubic. The ultrasound examination of the urinary bladder revealed a mild hepatomegaly with suspicious for granulomatous-like lesion. A cystoscopy was performed and one small biopsy was taken from the same anatomical region and sent to the Pathology Department. Specimen received in formalin consists of a small piece of soft creamy tissue with 0.1 cm in greatest dimension. Paraffin block was made; 5-micron section were cut and stained by hematoxylin and eosin staining method. Cystoscopy showed erythematous and fine irregularity of mucosa, especially in the right lateral wall of bladder. A microscopic isomorphic hematuria was found. The light microscopic study showed a couple of larvae as well as mononuclear inflammatory cell-infiltration (Fig. 1). Urine sediment showed hematuria. No typical granulomatous inflammation was present in histopathological investigation.



**Fig.1:** Pathological examination of bladder biopsy demonstrating VLM (H & E  $\times$  10) (Source: authors)

## Discussion

Several nematodes have been reported to produce VLM such as *Ascaris lumbricoides*, *A. suum* and *Capillaria hepatica*. *Toxocara canis* appears to be the primary causative and most common agent (3). *Toxocara* VLM is characterized by malaise, fever, pulmonary signs and symptoms, hepatomegaly, abdominal pain, anemia and occasionally failure to thrive (3). From this perspective, the distinctive features of our case were abdominal and suprapubic pain, a mild hepatomegaly with the absence of accompanying pulmonary signs and symptoms, plus anemia. Our case demonstrates that the diagnosis of *Toxocara* VLM can be difficult without paracilnical examination. In addition, once the diagnosis is established, antihelmintics treatment should start as soon as possible (11). The present case report recommends an educational program to be initiated to prevent and control VLM infection in both rural and urban people. Clinicians also should consider the clinical features of VLM.

## Acknowledgments

Authors thank Dr Abdolreza Kheirollahi MD for referring the patient to the Khorramabad Central Laboratory. The authors declare that there is no conflict of interests.

## References

1. Magnaval JF, Glickman LT, Dorchie P, Morassin B. Highlights of human toxocariasis. Korean J Parasitol. 2001; 39(1):1-11.
2. Muradian V, Gennari SM, Glickman LT, Pinheiro SR. Epidemiological aspects of visceral larva migrans in children living at Sao Remo Community, Sao Paulo (SP), Brazil. Vet Parasitol. 2005; 134:93-97.
3. Inan M, Sakru N, Vatansever U, Bilgi S. Visceral larva migrans presenting as acute abdomen in a child. J Ped Surg. 2006; 41:E7-E9.
4. Smith H, Holland C, Taylor M, et al. How common is human toxocariasis? towards standardizing our knowledge. Trends Parasitol. 2009; [Article in press].
5. Glickman LT, Magnaval JF, Domanski LM, et al. Visceral larva migrans in French adults: a new disease syndrome? Am J Epidemiol. 1987; 125(6):1019-34.
6. Farivar Kh, Rafat S. Visceral Larva Migrans (VLM): Report of 2 Cases. J Med Council Iran. 1992; 2(11): 94-97. [In Persian].
7. Rokni MB, Massoud J, Mowlavi Gh. Report of 10 cases of visceral larva migrans in Iran. Iranian J Pub Health. 2000; 29(1-4): 61-66.
8. Akhlaghi L, Ourmazdi H, Sarafnia A, et al. An investigation on the toxocariasis seroprevalence in children (2-12 years old) from Mahidasht Area of Kermanshah Province. J Iran Uni Med Sci. 2006; 52(13): 41-48. [In Persian].
9. Fallah M, Azimi A, Taherkhani H. Seroprevalence of toxocariasis in children under 10 years old of Hamadan. J Zanjan Uni Med Sci. 2005; 13(50): 44-50. [In Persian].
10. Sadjjadi SM, Khosravi M, Mehrabani D, Oryan A. Seroprevalence of *Toxocara* infection in school children of shiraz, southern Iran. J Trop Pediatr. 2000; 46: 327-330.
11. Taylor MR, Keane CT, O'Connor P, et al. The Expanded spectrum of toxocaral disease. Lancet. 1988; 26:692-5.