



Tehran University of Medical
Sciences Publication
<http://tums.ac.ir>

Iranian J Parasitol

Open access Journal at
<http://ijpa.tums.ac.ir>



Iranian Society of Parasitology
<http://isp.tums.ac.ir>

Original Article

Epidemiological Aspects of Canine Dirofilariasis in the North of Iran

*Sh Ranjbar-Bahadori¹, A Veshgini², D Shirani³, A Eslami², H Mohieddin¹, B Shemshadi¹, R Masooleh²

¹Veterinary College, Islamic Azad University, Garmsar branch, Garmsar, Iran

²Veterinary College, Islamic Azad University, Researches and Sciences Branch, Tehran, Iran

³Veterinary College, University of Tehran, Tehran, Iran

(Received 14 Sep 2010; accepted 18 Jan 2011)

ABSTRACT

Background: *Dirofilaria immitis* is an important parasite in dog and other carnivores. Our objective was study on incidence and periodicity of heartworm in north of Iran and using other methods for its diagnosis in addition to Parasitology exam.

Methods: This survey spanned two years, between 2006 and 2008. Blood samples were collected from 431 stray dogs distributed along north of Iran, the coastal areas of the Caspian Sea. The Knott's modified test was used for diagnosis of *D. immitis* and other filariae. Meanwhile, the periodicity of microfilaria in peripheral blood circulation was calculated and the imaging diagnosis techniques of four dogs that had positive results were done.

Result: Diagnostic parasitology results indicated that 16.01% of stray dogs were microfilaremic. Two different microfilariae were diagnosed: *D. immitis* in 13.69%, *Dipetalonema reconditum* in 1.86% and in 0.46% both of them. There was no statistically significant between infection to fiariae with sex and age of dogs. Also study on the periodicity of the presence of microfilaria in peripheral circulation showed that the highest rate of those was at 1 am and the lowest rate at 12 pm. Radiographic study showed distinctive signs with varied degrees of severity included: Tortuous and enlargement of main and lobar pulmonary artery, pulmonary parenchymal lesions and Right side heart enlargement that confirmed in electrocardiography. Also in echocardiographic images observed short parallel-sided images with the appearance of equal signs that indicated the presence of the heartworm.

Conclusion: These results showed that to obtain a reliable diagnosis of heartworm infection, imaging tests could support parasitological exams.

Keywords: *Dirofilaria immitis*, *Dipetalonema reconditum*, *Periodicity*, *Stray dogs*, *Iran*

*Corresponding author: Tel: # 989123900943, Fax: # 982324229700, E-mail: bahadori@iau-garmsar.ac.ir

Introduction

D*irofilaria immitis* or heartworm is the most important filarial parasite of dogs because it can cause some clinical signs (1). This worm lives in right ventricle, pulmonary artery and posterior vena cava and its microfilariae found in the peripheral circulation (2). Infection to *D. immitis* in carnivores especially dogs is worldwide and is reported from different regions of the world including Turkey (3), Japan (4), Brazil (5), Canada (6) and other countries (7, 8). *D. immitis* was first reported from a dog in Iran in 1969 (9). Then infection to heartworm was reported from different areas of Iran including Ardebil (10), Shiraz (11), Tehran (12), Tabriz (13), Tonekabon (14), and Mashhad (15).

Areas with suitable temperature and humidity are favor for mosquito as vector host of nematode and presence of these conditions in North of Iran (coastal border of Caspian Sea) and importance of stray dogs as reserve host of the infection in its transmission to other animals and even human (16) describe necessitate of this study. Therefore, we focused on rate of infection in stray dogs and determining of the periodicity of *D. immitis* microfilaria in peripheral circulation of an infected dog. Periodicity is a well-known phenomenon, which occurs with many filarioid worms, and various hypotheses put forward to explain periodicity have been comprehensively reviewed by Masuya (17). Females of *D. immitis* are ovoviviparous and the naked microfilariae may be found in the blood at all times, but there appears to be a periodicity superimposed on this, which varies with geographic location. The microfilarial periodicity of *D. immitis* in the peripheral circulation can increase the rate of infection of flies as a vector of heartworm (18).

Moreover, it is possible to find dogs with occult infections presenting no clinical sign,

in these cases using the parasitological method cannot help for diagnosis of the parasite. Therefore, the aim of this study was using the imaging diagnostic techniques included radiographic and echocardiographic exams for diagnosis of heartworm.

Situation of area

The present study was done in northern regions of Iran included three provinces (Golestan, Mazandaran and Gilan) that are in coastal boarder of the Caspian Sea with suitable temperature (15-25°C) and humidity (70-90%) for development of parasites (2).

Preparation of samples

A total of 431 stray dogs in different regions of above-mentioned area (110 samples Golestan, 220 samples Mazandaran, and 101 from Gilan) were trapped in two years, between 2006 and 2008. After determination of their age and sex, one ml of blood was withdrawn from branchial vein and blood samples were transferred to Parasitology Laboratory of Veterinary College, Islamic Azad University, Garmsar branch.

Diagnostic Parasitological test (Knott's test)

In Knott's method, blood samples were mixed with formaldehyde 2% and the sediments from prepared samples were searched for microfilaria and identification of them were performed using a valuable key (19).

Determination of the periodicity of microfilaria

For determination of the periodicity of microfilaria in peripheral blood circulation, blood samples were collected from an infected dog each hour for 72 hours. Then number of microfilaria in each ml of the blood sample was calculated and expressed as average of those in each hour.

**Imaging diagnosis techniques
(Electrocardiography and radiography)**

Imaging diagnostic techniques included radiography, echocardiography and electrocardiography of four dogs that confirmed positive results with Knott's test. Dorsoventral and left lateral thoracic radiographs were taken. Echocardiography and electrocardiography were performed in these dogs.

Statistical methods

Analyses of all variable were computed using Chi-square test and $P < 0.05$ was expected significant.

Results

Of 431 studied stray dogs, 16.01% were microfilaremic and two different microfilariae were diagnosed: *D. immitis* in 13.69%, and *Dipetalonema reconditum* in 1.86% and 0.46% of both of them. The species of microfilaria and their morphology detected from prepared smear and Knott's test after adding Geimsa stain. Frequency and percentage of the blood filariasis of stray dogs in north of Iran based on different provinces (Golestan, Mazandaran, and Gilan provinces) are seen in Table 1. A total of 325 (75.41%) male dogs and 106 (24.59%) females were included and relationship be-

tween infection to filariae and sex of dogs was not significantly. There was no statistically significant difference between infection and age of dogs, Table 2. Study on the periodicity of microfilaria in the peripheral blood circulation showed that maximum and minimum numbers of those were seen at 1 a.m. (13316±57 microfilaria) and 12 p.m. (6681±23 microfilaria) respectively (Fig. 1).

In the radiographic study, all the four selected dogs presented at least one of the following distinctive radiographic signs with varied degrees of severity (Table 3); *i*) Right heart enlargement included increased sternal contact on the lateral view and inverted *D* shaped on the dorsoventral or ventrodorsal view; *ii*) Tortuous and enlargement of lobar pulmonary artery; *iii*) Enlargement of main pulmonary artery; *iv*) Large and blunted peripheral pulmonary artery; *v*) Pulmonary paranchymal lesions (bronchial, interstitial, vascular and alveolar pattern). Radiographic images of an infected dog that analyzed in the study are shown in Fig. 2.

In electrocardiography, right ventricular enlargement is present (Deep Q waves in leads II, III and avf). In addition, in the echocardiographic study, short parallel-sided images with the appearance of equal signs were observed that confirmed the presence of the heartworm.

Table 1: Frequency and percentage of the blood filariasis of stray dogs in north of Iran based on province

Province	<i>D. immitis</i>		<i>Dip. reconditum</i>		Mixed infected		non-infected		Total	
	No.	%	No.	%	No.	%	No.	%	No.	%
Golestan	17	3.94	5	1.16	0	0	88	20.42	110	25.52
Mazandaran	23	5.37	1	0.23	1	0.23	195	45.24	220	51.04
Gilan	19	4.41	2	0.46	1	0.23	79	18.33	101	23.43
Total	59	13.69	8	1.86	2	0.46	362	83.99	431	100

Table 2: Frequency and percentage of the blood filariosis of stray dogs in north of Iran based on age

Age	<i>D. immitis</i>		<i>Dip. reconditum</i>		Mixed infected		non-infected		Total	
	No.	%	No.	%	No.	%	No.	%	No.	%
<one year	0	0	0	0	0	0	19	5.25	19	4.41
1-5 year	26	44.07	5	62.5	0	0	201	55.53	232	53.83
6-10 years	27	45.76	3	37.5	2	100	123	33.97	155	35.96
>10 years	6	10.17	0	0	0	0	19	5.25	25	5.80
Total	59	100	8	100	2	100	362	100	431	100

Table 3: Radiographic findings in four dogs infected to *Dirofilaria immitis*

Radiographic finding	No. 1	No. 2	No. 3	No. 4
	Right heart enlargement	Increased sternal contact on the lateral view	+	+
Inverted <i>D shaped</i> on the dorsoventral or ventrodorsal view		+	+	+
Enlargement of main pulmonary artery	+	+	+	+
Large and blunted peripheral pulmonary artery	+	+	+	+
Alveolar pattern	+	+	+	+
Interstitial pattern	+	+	+	+
Bronchial pattern	+	+	+	+
Vascular Pattern	+	+	+	+
Tortuous and enlargement of lobar pulmonary artery	+	+	+	+
Non vascular linear marking and nodular opacities due to pulmonary fibrosis	+	+	+	+
Hepatomegaly	+	+	+	+
Ascitis	+	+	+	+
Comment	Bulging of PA was a prominent finding at 12-2 o'clock of heart shadow			+

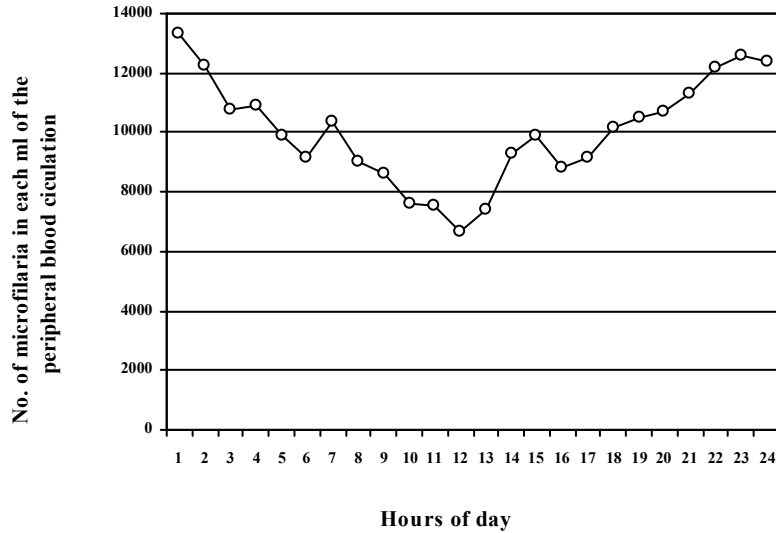


Fig. 1: Periodicity of the presence of microfilaria of *Dirofilaria immitis* in the blood of an infected dog

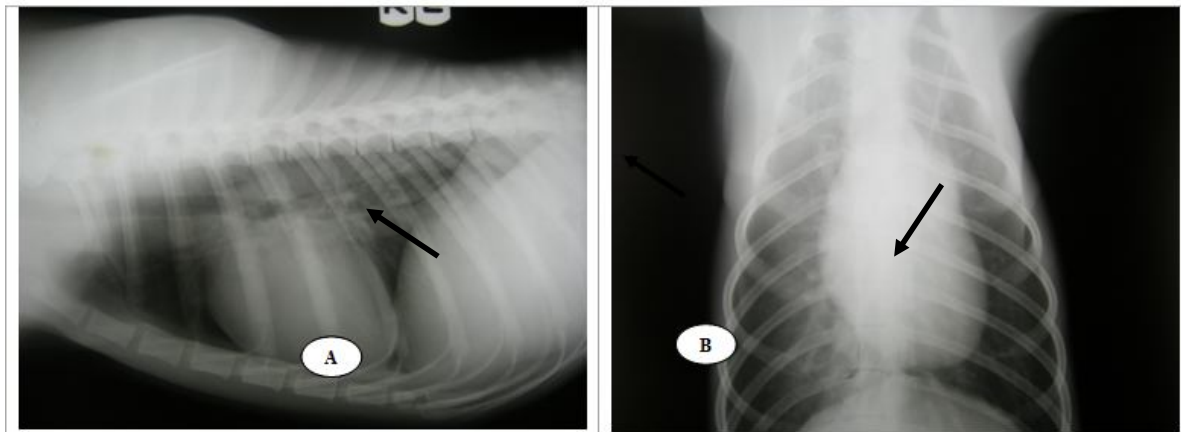


Fig. 2: Thoracic radiographs: (A) Left Lateral view showed cardiac enlargement, tortuous and enlargement of lobar pulmonary artery (arrow), increased sternal contact on the lateral view. (B) Dorso-ventral view showed bulging of pulmonary artery that it was a prominent finding at 12-2 o'clock of heart shadow (arrow)

Discussion

Canine dirofilariasis is a disease of worldwide distribution. However, endemic areas are those with temperate, tropical, and subtropical climatic conditions (20). In general, the coastal areas in North of Iran presented a higher prevalence of heartworm infection (16.0%) than most other area in Iran (11, 13-15, 21). These areas have favorable climatic

conditions with high moisture, several species of mosquitoes, and a large number of stray dogs that do not receive antiparasitic drugs and wild carnivores as reserve host of heartworm. Meanwhile, the prevalence of *Dip. recunditum* was 1.86% and that was similar to previous findings (13, 14).

The prevalence of microfilaria (especially *D. immitis*) in dogs can largely vary in different regions of the world. For instance, prevalence in Argentina, Taiwan, Korea and Brazil is reported as 5.1% (8), 25.0% (22), 40.0% (23) and 5.4% (5), respectively. This variation can be due to certain epidemiological factors, such as distribution of the vector, animal living situation, and average age of the study population. In Mexico, national prevalence of infection was reported 7.3%, showing that in coastal areas the prevalence is higher (19.6%) (24). There was no statistically significant difference between males and females dogs and this is similar to another findings (5). In addition, there was no significant difference among infected dogs and their ages. Similar findings were reported previously (5, 12-14).

Study on the periodicity of microfilaria in peripheral blood circulation showed a nightly increase in number of circulating microfilaria (nightly periodicity) and these results are similar to other findings (12). So, periodicity of presence of microfilaria of *D. immitis* was shown in different regions of world (25). Nevertheless, there is deference between maximum and minimum of presence of microfilaria in blood circulation in duration of day between northern and southern hemisphere. in southern hemisphere, in contrary to northern hemisphere, the maximum presence of microfilaria in blood circulation in 11 am and the minimum of them was in 10 p.m. (daily periodicity) (26). Knott's test should be performed to confirm microfilaremia and not for diagnosis of heartworm infection. So, four infected dogs were analyzed with diagnostic imaging techniques for using them to support parasitological exams. Severity and duration of parasite infestation in these dogs were unknown since the infestation was spontaneous. Therefore, dogs without radiographic abnormalities may have had minor infestations or heartworms may not have been present suffi-

ciently long for the development of radiographic change (27). One of the important diagnostic features in canine heartworm disease is the presence of radiographic changes, which occur primarily in the right side of the heart and its associated vessels (5, 8, 19, 28). Typical (near pathogonomic) signs of heartworm vascular disease are enlarged, tortuous and often truncated peripheral intralobar and interlobar branches of the pulmonary arteries, particularly in the diaphragmatic lobes. These findings are accompanied by variable degrees of pulmonary parenchymal disease and in the worst cases; the right heart enlarges. Pulmonary parenchymal changes in dirofilariosis were more severe around the branches of the pulmonary arteries and together with the arterial change, produced a radiographic picture that was characteristic of heartworm disease. These parenchymal changes were classified into alveolar, interstitial, bronchovascular and mixed pattern (29). The alveolar and mixed patterns produced dense radiopacities but the interstitial patter was less dense and remained in spite of treatment otherwise of two other types. Evaluation of pathologic changes in radiographs, particularly surrounding the main pulmonary artery and its branches, can lead to a diagnosis of dirofilariosis, also aid in assessment of the severity of the disease and assist in planning a treatment program. Therefore, dirofilariosis caused right sided heart failure, if congestive heart failure occurred; the radiographic appearance was more complex. Interstitial edema occurred first and produced an interstitial pattern. An alveolar and mixed pattern appeared (28). These parenchymal changes can produce by live or dead worms, their microfilaria, and perhaps an immunologic response.

Electrocardiographic (ECG) changes in heartworm disease have been reported. In general, ECG criteria for right ventricular hypertrophy (RVH) are seen in dogs with

chronic or more severe heartworm disease (30). The right ventricle of dogs with heartworm disease appears to dilate prior to hypertrophy, the ECG is not sensitive to right ventricular dilatation (31), and the degree of right ventricular enlargement is variable depending on the stage of the disease.

In echocardiographic study, the body wall of adult heartworm is highly echogenic and produces distinctive, short parallel-sided images with the appearance of equal signs were the imaging plane cuts across loops of the parasite. However, it is not an efficient method of making this diagnosis, particularly in lightly infected dogs, since the worms often are limited to the peripheral branches of the pulmonary arteries beyond the echographic field of view. However, when heartworms are numerous, they are more likely to be present in the main pulmonary artery or within right side of heart where they can be imaged easily (29).

In conclusion, these findings showed that using the imaging tests can support parasitological methods to obtain a reliable diagnosis of heartworm infection.

Acknowledgements

The authors would like to thank the financial support from the Research Vice Chancellor of Islamic Azad University, Garmsar branch. The authors declare that there is no conflict of interests.

References

1. Brown HW, Neva FA. Basic clinical Parasitology. 5th ed. Singapore; 1993.
2. Eslami A. Veterinary Helminthology. Tehran University Publication; 1998 (in Persian).
3. Atas AD, Ozcelik S, Saygi G. The occurrence of helminth species in stray dogs, their prevalence and significance to public health in Sivas. Acta Parasitol Turcica. 1997; 21 (3): 305-9.
4. Hatsushika R, Okino T, Shimizu M, Ohyama F. The prevalence of dog heart worm (*Dirofilaria immitis*) infection in stray dogs in Okayama, Kawasaki. Japan Med J. 1997; 3, 4: 75-83.
5. Reifur L, Thomaz-Soccol V, Montiani-Ferreira F. Epidemiological aspects of filariasis in dogs on the coast of Parana state, Brazil: with emphasis on *Dirofilaria immitis*. Vet Parasitol. 2004; 122: 273-86.
6. Slocombe JOD, Villeneuve A. Heart worm in dogs in Canada in 1991. Canadian Vet J. 1993; 34 (10): 630-3.
7. Chen KY, Liang S. Blood chemistry of dogs with heart Worm in the Taipei area. J Chinese Soc Vet Sci. 1993; 19(2): 130-6.
8. Rosa A, Ribicich M, Betti A, Kistermann N, Cardillo N, Basso N, Hallu R. Prevalence of canine dirofilariosis in the city of Buenos Aires and its outskirts (Argentina). Vet Parasitol. 2002; 109: 261-4.
9. Sadighian A. Helminth parasites of stray dogs and jackals in Shahsavar area, Caspian region, Iran. J Helminth. 1969; 2: 372-4.
10. Bokai S, Moobedi A, Mohebali M, Hoseini H, Nadim A. Study on prevalence of dirofilariosis in Meshkinshahr-Northwest of Iran. J Fac Vet Med Tehran Univ. 1998; 53(1, 2): 23 (in Persian with English abstract).
11. Jafari S, Gaur NS, Khaksar Z. Prevalence of *Dirofilaria immitis* on dog of Fars province of Iran. J Appl Anim Res. 1996; 9 (1): 27-31.
12. Meshgi B, Eslami A. Study on filariosis of sheepdogs around of Tehran. J Fac Vet Med Tehran Univ. 2001; 55(4): 53-7 (in Persian with English abstract).
13. Meshgi B, Eslami A, Ashrafi Helan J. Epidemiological survey of blood fi-

- lariae in rural and urban dogs of Tabriz. J Fac Vet Med Tehran Univ. 2002; 57(4): 59-63 (in Persian with English abstract).
14. Ranjbar-Bahadori Sh, Eslami A, Meshgi B, Mohammad Mohtasham R. Study on blood filaria of dogs in Tonekabon. J Fac Vet Med Tehran Univ. 2005; 60(4): 353-6 (in Persian with English abstract).
 15. Razmi Gh. Study on situation of infection to dogs of Mashhad to types of filaria. J Fac Vet Med Tehran Univ. 1999; 54(1): 5-7 (in Persian with English abstract).
 16. Salahi-Moghadam A, Moobedi A, Bani Hashemi SJ. Case report of *Dirofilaria* in Hydrocoel of a child with 5 years old age, 3rd National Congress of Parasitology, sari, Iran. Mazandaran medical sciences university Publication. 2000.
 17. Masuya T. Studies on the mechanism of the filarial periodicity - The autofluorescence in the microfilariae and their periodicity. Jap J Parasitol. 1976; 25(4):283-312.
 18. Rhee JK, Yang SS, Kim HC. Periodicity exhibited by *Dirofilaria immitis* microfilariae identified in dogs of Korea. Korean J Parasitol. 1998; 36(4): 235-9.
 19. Ettinger S, Feldman FC. Textbook of Small Animal Internal Medicine. WB Saunder, New York; 2000.
 20. Bolio-Gonzalez ME, Rodriguez-Vivas RI, Sauri-Arceo CH, Gutierrez-Blanco E, Ortega-Pacheco A, Colin-Flores RF. Prevalence of the *Dirofilaria immitis* infection in dogs from Merida, Yucatan, Mexico. Vet Parasitol. 2007; 148: 166-9.
 21. Sanjar M, Niak A, Khatibi S. Dirofilariasis in the dog in Iran. Vet Rec. 1969; 52: 204.
 22. Wu CC, Fan PC. Prevalence of canine dirofilariasis in Taiwan. J. Helminthol. 2003; 77: 83-8.
 23. Song KH, Lee SE, Hayasaki M, Shiramizu K, Kim DH, Cho KW. Seroprevalence of canine dirofilariosis in South Korea. Vet Parasitol. 2003; 114: 231-6.
 24. Labarthe N, Guerrero J. Epidemiology of heartworm: what is happening in South America and Mexico. Vet Parasitol. 2005; 133: 149-56.
 25. Hawking F, Adams WE, Worms MJ. The periodicity of microfilariae. Trans R Sec Trop Med Hyg. 1964; 58(2): 178-94.
 26. Matola YG. Periodicity of *Dirofilaria immitis* microfilariae in a dog from Muheza district, Tanzania. J Helminthol. 1991; 65(1): 76-8.
 27. Losonsky JM, Thrall DE, Lewis RE. Thoracic radiographic abnormalities in 200 dogs with spontaneous heartworm infestation. Vet Radiol. 1983; 24(3): 120-3.
 28. Carlisle CH. Canine Dirofilariosis: its radiographic appearance. Vet Radiol. 1980; 21(3): 123-30.
 29. Guidelines. 2005 Guidelines for the diagnosis, prevention and management of heartworm (*Dirofilaria immitis*) infection in dogs. Vet Parasitol. 2005; 133: 255-66.
 30. Calvert CA, Losonsky JM, Brown J, Lewis RE. Comparisons of radiographic and electrocardiographic abnormalities in canine heartworm disease. Vet Radiol. 1986; 27(1): 2-7.
 31. Rawlings CA, McCall JW, Lewis RE. The response of the canine's heart and lung to *Dirofilaria immitis*. J Am Anim Hosp Assoc. 1978; 14: 17-32.