



Tehran University of
Medical Sciences
Publication
<http://tums.ac.ir>

Iranian J Parasitol

Open access Journal at
<http://ijpa.tums.ac.ir>



Iranian Society of
Parasitology
<http://isp.tums.ac.ir>

Original Article

Molecular and Pathological Study of Bovine Aborted Fetuses and Placenta from *Neospora caninum* Infected Dairy Cattle

N Salehi¹, *H Haddadzadeh², J Ashrafihelan¹, P Shayan², A Sadrebazzaz³

¹ Dept. of Pathobiology, Faculty of Veterinary Medicine, University of Tabriz, Tabriz-Iran

² Dept. of Parasitology, Faculty of Veterinary Medicine, University of Tehran, Tehran, Iran

³ Razi Serum and Vaccine Research Institute, Mashhad, Iran

(Received 2 May 2009; accepted 5 July 2009)

Abstract

Background: The objective of the study was to evaluate the presence of *Neospora caninum* organisms in the brain of aborted fetuses and placentas of full-term calves born of seropositive cows.

Methods: During 2006-2007, 12 brains of aborted calves from *Neospora* seropositive cattle and 7 placentas from seropositive dams giving birth to full-term calves, from four dairy cattle farms located around Tehran province, Iran were examined by Nested-PCR and histopathology techniques.

Result: The Nested-PCR demonstrated that all of 12 aborted fetal brain samples and 5 of 7 placentas were infected by *N. caninum*. Mild to severe placentitis was observed in 5 placentas. Severe hyperemia and perivascular and perineuronal edema revealed in all fetal brain. In 3 out of 12 brains, scattered foci of hemorrhages, neuropilar necrosis and gliosis were present. In addition, nonpurulent encephalitis with severe lymphohistiocytic perivascular cuffing in one case and a small tissue cyst like *Neospora caninum* cyst in other calf were observed.

Conclusion: Our results confirmed the molecular and histopathologic findings of other studies about *Neospora caninum* infection and it seems to support the hypothesis that *Neospora* infection is associated with bovine abortion in Iran.

Keywords: *Neospora caninum*, Nested-PCR, Histopathology, Fetal brain, Placenta

* Corresponding author: Tel: +98 21 66924469, Email: hhadad@ut.ac.ir

Introduction

Bovine neosporosis, caused by the apicomplexan protozoan parasite *Neospora caninum*, was initially recognized in 1989 (1) and is now reported as a leading infectious cause of reproductive failure in dairy cattle in countries worldwide (2-8). Transplacental transmission is considered the major route of transmission of *N. caninum* in cattle (9). Fetal bovine infection by *Neospora caninum* can lead to abortion or birth of a congenitally infected calf with or without clinical manifestations (10). Infection of the fetus likely occurs following a recrudescence of a latent infection or a new infection. The organism probably infects fetal tissues after first infecting the placenta (11, 12).

A range of diagnostic tools has been proved useful to detect *Neospora* infection. Bovine neosporosis can be diagnosed using indirect fluorescent antibody test (IFAT) and enzyme-linked immunosorbent assay (ELISA) and in fetuses using methods such as histopathology (HP), immunohistochemistry (IHC) and polymerase chain reaction (PCR) (13, 14).

One of the most widely used techniques is fetal histopathology of brain along with several other organs such as the heart, liver, lung, kidney and skeletal muscles, in an attempt to detect lesions characteristic of protozoan infection, combined or not with immunohistochemical (IHC) examination (3, 15, 16). Typical fetal lesions, which are not pathognomonic, include multifocal nonsuppurative necrotizing encephalitis and nonsuppurative myocarditis with or without focal necrosis in the liver (8, 15, 17). Although the placenta is not always available, the presence of a non-suppurative placentitis and necrosis has been described in abortion in early gestation (18, 19). However, pla-

centitis always seems to be mild (12, 21). The most frequent and almost pathognomonic CNS lesion in bovine fetuses is the presence of multifocal discrete foci of necrosis, particularly in the brain and to lesser extent in the cord. The necrotic areas are fairly well circumscribed, have necrotic centers and are surrounded by rim of glial cells and macrophages. In advanced lesions, the necrotic area may be completely replaced by macrophages and a few glial cells, which make the lesions, appear as discrete granulomas. Other CNS lesions include mild nonsuppurative meningoencephalomyelitis. Tissue cysts are primarily present in the CNS and rarely in skeletal muscles and retina. *Neospora caninum* tissue cysts are rarely seen (22). IHC is relatively insensitive as a confirmatory test for neosporosis because parasite numbers in infected tissue can be very low, possibly leading to false negatives (23-25). Furthermore fetal serology has been used to confirm *N. caninum* abortion in individual fetuses, but the assay is not highly sensitive (14, 16), but PCR techniques have been useful as diagnostic tools for detection of the parasite in aborted bovine fetuses (24-27). PCR methods generally have a higher sensitivity and specificity than IHC methods and the ability to amplify small amounts of *Neospora* DNA in a larger quantity of tissue (28). Several PCR based methods have been developed in the last few years targeting the parasite ITS1 region (29) and the repeated *Neospora*-specific Nc5 sequence (30) with different modifications, such as nested or seminested PCR test.

In Iran, there are some studies about *Neospora* (13, 31-36). Results based on seroprevalence of *N. caninum* in aborted dairy cattle showed that neosporosis should be regarded as a cause of economic loss in dairy cattle (31, 32).

The objective of the study was PCR detection and histopathologic analysis for *N. caninum* in the brain of aborted fetuses and placentas.

Material and Methods

Sampling

The study included four dairy cattle farms around Tehran, capital of Iran, from which *N. caninum* antibodies had been detected by ELISA (IDEXX herdcheck kit, Germany). The range of seropositive cows in those dairies was 38.8%. *Neospora* seropositive dairies were monitored from June to November 2007, and with the owner's cooperation, 12 brain aborted calves and 7 placentas from seropositive cattle giving birth to full-term calves were obtained. The samples were immediately transported to the laboratory on cold conditions. The brains were removed aseptically and some parts of brain and placenta tissue were fixed in 10% buffered formalin (pH 7.2) for histopathology analysis. Approximately 5-10 g of samples taken selectively from different anatomic regions were homogenized in 20 ml of sterile PBS containing 2% antibiotic, transferred to microtubes, and then stored at -20°C until further use.

Histopathology

The tissue specimens from central nervous system and placenta were sampled and cut into pieces and fixed in 10% buffered formaldehyde solution. The formaldehyde-fixed tissue specimens were processed in a tissue processor (Jung histokinette 2000, Leica, Germany), paraffin blocks were made, and 5-6 microns thick sections were serially cut with a microtome (Jung histocuts, Leica, Germany) and stained with hematoxylin and eosin (H&E) (37). Histopa-

thologically, the sections were examined by light microscopy (Olympus, CH36RF200, Japan) and digitally photographed with a photomicrograph (Olympus DP12, U-TVO.5XC-2, Japan).

DNA isolation

Total DNA was extracted from 300µl of homogenized suspension using a Qiagen DNAeasy Tissue kit (Qiagen, GmbH, Germany) according to manufacturer's instructions. Electrophoresis of each DNA sample on 2% agarose gel in 1X TBE buffer was undertaken to check the integrity of the DNA. A 60 µl aliquot of total DNA was produced from each sample and stored at -20 °C until required for analysis.

PCR amplification

The *N. caninum* specific primers used in this study were modified Np21⁺ and Np6⁺ primers (30) based on the Nc-5 gene specific for *N. caninum*. In order to improve the sensitivity of this PCR, internal primers designated Np7 (5'gggtgaaccgagggagtgtg3') and Np10 (5'tcgtccgcttgcctatgaat3') were designed using available sequence data for the Nc-5 gene (GenBank accession no. X84238). The PCR mixture of 50µl contained 1µg of target DNA, 2mM MgCl₂, 10xreaction buffer (50mM KCl, 10mM Tris-HCl [pH8.3], 10pmol of each PCR primer, 200µM each dNTP, and 1U of *Taq* DNA polymerase (CinnaGen, Iran). PCRs were performed in a thermocycler (Techgene-Techne, Germany) for 35 cycles of denaturation at 104 °C for 45S, annealing at 64 °C for 45S, and extension at 72 °C for 45S. For nested PCR, second-round primers Nc7 and Nc10 were used 1µl of amplicon solution from first-round PCR amplification as target DNA with the same PCR mixture subjected to 35 cycles of denaturation at 104 °C for

45S, annealing at 64°C for 45S, and extension at 72 °C for 45S. Positive (*Neospora* DNA) and negative controls (sterile water) were included in each PCR run. Amplification products were analyzed by electrophoresis through a 2% agarose gel for the specific *N. caninum* PCR.

Results

IgG antibodies against *N. caninum* were detected in 298 of 768 blood samples (38.8%). These *Neospora* seropositive dairies were monitored from June to November 2007, and with the owner's cooperation, 12 brain aborted calves and 7 placentas from seropositive cattle giving birth to full-term calves were obtained. In histopathology study, severe congestion and edema, several focal hemorrhages, mild multifocal lymphoplasmocytic placentitis, and degenerative change of cotyledons were present in 6 of 7 cases (Table 1); also severe lymphohistiocytic placentitis were shown in one sample. There were no intracellular or extracellular tachy-

zoites or tissue cysts of *N. caninum*. Histopathologic examination of central nervous system revealed a moderate to severe hyperemia and perivascular and perineuronal edema in all cases (Table2). In 3 out of 12 cases, scattered foci of hemorrhages, neuropilar necrosis and gliosis (glial nodules) were present. In addition, nonpurulent encephalitis with severe lymphohistiocytic perivascular cuffing in one case (Fig. 1) and a small tissue cyst like *Neospora caninum* cyst in other case were observed (Fig. 2). There were no intracellular or extracellular tachyzoites of *N. caninum*.

For PCR detection, DNA was successfully extracted from all samples. The primers Np21 and Np6 were used to amplify 328 bp of the above sequences. Moreover, Np7 and Np10 amplified 1108 bp of the same regions. The Nested-PCR demonstrated that all of 12 aborted fetal brain samples and 5 of 7 placentas were infected by *N. caninum* (Fig. 3).

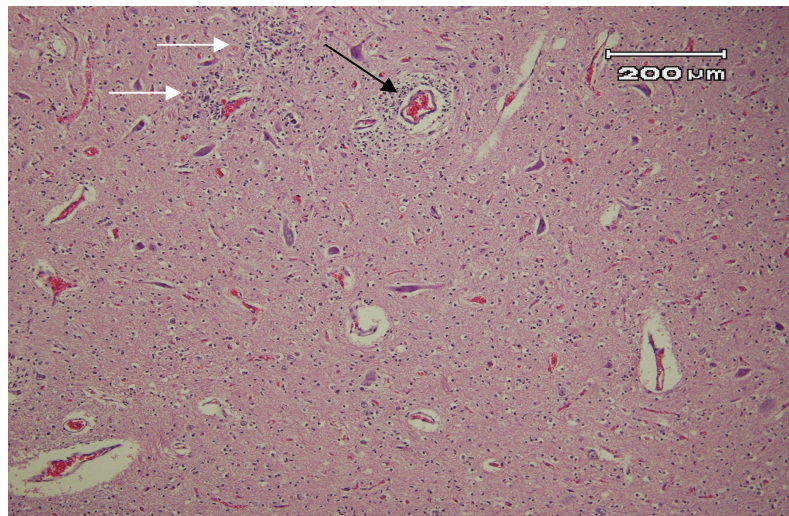


Fig. 1: Lesions of neosporosis, hyperemia, focal gliosis (white arrows) and nonsuppurative encephalitis (black arrow) with lymphohistiocytic perivascular cuffing are present (H&E, 100×)

Table 1: The histopathologic changes of the placentas of the aborted calves due to *Neospora caninum*

Case No.	Histopathologic changes							
	Congestion	edema	Focal hemorrhages	Degenerative changes in placenta (trophoblasts of placental villi)	Foci of necrosis and desquamation in placenta (trophoblasts of Placentitis	Tachyzoite of the parasite	Tissue cyst	
1	severe	severe	several	Severe hydropic change of trophoblasts cells	several	Mild (lymphoplasmocytic with few PMN)	-	A small cyst in the brain
2	severe	severe	several	Severe hydropic change	several	Mild (lymphoplasmocytic with few PMN)	-	-
3	severe	severe	several	Severe hydropic change	several	Mild (lymphoplasmocytic with few PMN)	-	-
4	severe	severe	several	hydropic change, syncytial formation with viral inclusion bodies	several	Acute inflammation (the lesions like IBR)	-	-
5	severe	severe	several	Mild hydropic change	several	Severe (lymphohistiocytic)	-	-
6	severe	severe	several	Mild hydropic change	several	-	-	-
7	severe	severe	-	-	-	-	-	-

Table 2: The histopathologic changes of the central nervous system in aborted calves due to *Neospora caninum*

Case No.	Histopathologic changes									
	Hyperemia	edema (perivascular & perineuronal)	Focal hemorrhages	Focal necrosis	Foci of gliosis (glial nodules)	Foci of granulomatous reaction	Perivascular cuffing (PVC)	nonpurulent encephalitis	Tachyzoites of the parasite	Tissue cysts
1	severe	severe	several	several	several	-	-	-	-	A small cyst in the brain
2	moderate	moderate	Several (small foci)	several	several	-	Around of an arteriole	-	-	-
3	severe	severe	Several (small foci)	multiple	multiple	-	Severe (lymphohistiocytic)	severe	-	-
4	severe	severe	Several (small foci)	-	-	-	-	-	-	-
5	severe	severe	Several (large foci)	-	-	-	-	-	-	-
6	severe	severe	-	-	-	-	-	-	-	-
7	severe	severe	-	-	-	-	-	-	-	-
8	severe	severe	-	-	-	-	-	-	-	-
9	severe	severe	-	-	-	-	-	-	-	-
10	severe	severe	-	-	-	-	-	-	-	-
11	severe	severe	-	-	-	-	-	-	-	-
12	severe	severe	-	-	-	-	-	-	-	-

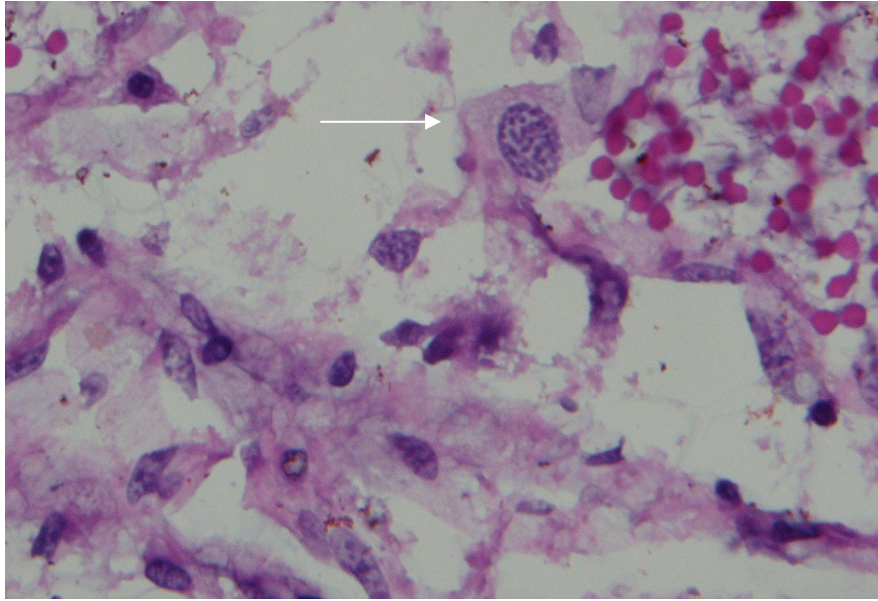


Fig. 2: Lesions of neosporosis, a small neospora-like cyst (arrow) in the brain of a calf aborted due to *N. caninum* (H&E, 400×)

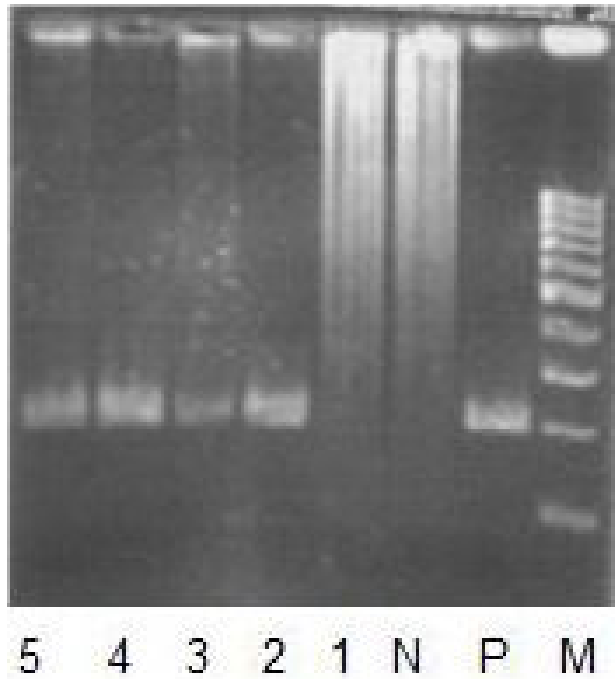


Fig. 3: Gel image showing a nested PCR: M: marker, P: positive control of *N. caninum* DNA, N: negative control, Lane 1,2: placenta samples, Lane 3,4,5: Brain samples

Discussion

The apicomplexan parasite *Neospora caninum* is the most frequently diagnosed abortifacient in dairy cattle worldwide (4). Endogenous transplacental transmission, resulting from recrudescence of bradyzoite cysts in a chronically infected dam is the principle natural route of infection (23). It has also been shown that cattle may abort after exogenous transplacental transmission, following ingestion during pregnancy of oocysts from the faeces of dogs, the definitive host (18, 38). Concerning fetal diagnosis, detection of compatible lesions by histology and parasites by PCR in brain (as well as heart and liver) are the best choices for fetal diagnosis (19). In the present study, the histopathology changes observed in the *Neospora* PCR positive placentas of seropositive cows were in agreement with the mild lesions and limited tissue distribution of *N. caninum* observed in congenitally infected calves (39). In two retrospective studies, placentas of aborted calves were examined. Ten of 19 in one study and 11 of 19 in the other study had placentitis (20, 21). However, *N. caninum*-like organisms were found histologically in only one placenta (20). In another study, placenta of one aborted fetus had *N. caninum* tachyzoites (12, 40). In the present study, 6 of 7 of samples had placentitis and *N. caninum* tachyzoite was not identified by HP; however, the small number of placentas was studied. In addition, there are two hypotheses to explain the complete absence or the presence of only small numbers of organisms in the placentas of *N. caninum* seropositive cows: 1) the infection occurs in midgestation and at time of parturition *N. caninum* organisms are no longer present in the placentas, 2) *N. caninum* has a tropism for the nervous tissues and is not prevalent in placentas (12). Inflammatory lesions suggestive of protozoan infection (13, 41) were found in PCR positive fetal

brain in our study were in agreement with another reports in which fetal brains were affected (3, 21, 42, 43, 31, 35). In this study, tissue cyst like *N. caninum* organisms was identified in one brain sample in HE-stained sections. Tissue cysts are often round to oval, up to 107 μm long. The cyst wall is smooth and up to 4 μm thick, depending upon how long the infection has existed. In most tissue cysts the cyst wall is 1 to 2 μm thick (13, 43). The observed cyst is in accordance with the morphology of *Neospora* cyst that is described in cattle (13, 35, 43-45).

In this study, 100% of *N. caninum* fetal infection cases and 71% of placental infection were diagnosed by nested PCR; this value was different as reported in other studies in Iran (13, 35, 46) and in Mexico (45). Nested-PCR were developed and used in studies on pathogenesis of bovine neosporosis. The specifically designed PCR analyses showed that nested-PCR procedure (to increase sensitivity and specificity) was necessary to detect *N. caninum* infected fetuses (13). There is an up to 1,000 times increased efficiency at generating second-round amplicons (47). Our study is consistent with previous studies showing tissue parasites detected most frequently in brain by PCR (11). In this study, some of the aborted fetuses showed suggestive lesions of neosporosis by HP like Morales *et al.* (2001) and in Sager *et al.* (2001) studies. Furthermore, good agreement between HP and PCR was observed and the aborted fetal brains and placenta have been shown as a reliable tissue for PCR analysis.

In conclusion, our findings confirmed the histopathology and molecular results of other studies about *Neospora caninum* infection and it seems to support the hypothesis that *Neospora* infection is associated with bovine abortion in Iran. Based on these results, it may be prudent to prevent dogs from

ingesting placentas and aborted fetuses from seropositive cows. However, organisms are more frequently observed in aborted fetuses (20) than in placentas of full-term calves from seropositive dams, the fetuses are certainly the main source of canine infection (12).

Acknowledgements

The study was supported financially by Faculty of Veterinary Medicine, University of Tehran. The authors declare that they have no conflicts of interest.

References

1. Thilsted JP, Dubey JP. Neosporosis-like abortions in a herd of dairy cattle. *J Vet Diagn Investig.* 1989; 1:205–9.
2. Anderson ML, Palmer CW, Thurmond MC, Picanso JP, Blanchard PC, Breitmeyer RE, Layton AW, McAllister M, Daft B, Kinde H. Evaluation of abortions in cattle attributable to neosporosis in selected dairy herds in California. *J Am. Vet Med Assoc.* 1995; 207:1206–10.
3. Anderson ML, Blanchard PC, Barr BC, Dubey JP, Hoffman RL, Conrad PA. *Neospora*-like protozoan infection as a major cause of abortion in California dairy cattle. *J Am Vet Med Assoc.* 1991; 1108:241–4.
4. Dubey JP. Recent advances in *Neospora* and neosporosis. *Vet Parasitol.* 1999; 84:349–67.
5. Otter A, Jeffrey M, Griffiths IB, Dubey JP. A survey of the incidence of *Neospora caninum* infection in aborted and stillborn bovine fetuses in England and Wales. *Vet Rec.* 1995; 136:602–6.
6. Thornton RN, Gajadhar A, Evans J. *Neospora* abortion in a dairy herd. *N Z Vet J.* 1994; 42:190–1.
7. Wouda W, van den Ingh TS, van Knapen F, Sluyter FJ, Koeman JP, Dubey JP. *Neospora* abortion in cattle in The Netherlands. *Tijdschr Diergeneeskd.* 1992; 117:599–602.
8. Timothy V, Baszler L, Gay JC, Maureen T. Long, Bruce A. Mathison. Detection by PCR of *Neospora caninum* in Fetal Tissues from Spontaneous Bovine Abortions. *J Clin Microbiol.* 1999; 37(12): 4059–64.
9. Dubey JP. Review of *Neospora caninum* and neosporosis in animals. *Korean J Parasitol.* 2003; 41, 1–16.
10. Helman RG, Stair EL, Lehenbauer TW, Rodgers S, Saliki TJ. *Neosporal* abortion in Oklahoma cattle with emphasis on the distribution of brain lesions in aborted fetuses. *J Vet Diagn Invest.* 1998; 10:2102–05.
11. Dubey JP, Schares G. Diagnosis of bovine neosporosis, *Vet Parasitol.* 2006; 140(1-2):1-34.
12. Bergeron N, Girard C, Julie Pare', Gilles Fecteau, Robinson J, Baillargeon P. Rare detection of *Neospora caninum* in placentas from seropositive dams giving birth to full-term calves. *J Vet Diagn Invest.* 2001;13:173–5.
13. Sadrebazzaz A, Habibi G, Haddadzadeh H, Ashrafi J. Evaluation of bovine abortion associated with *Neospora caninum* by different diagnostic techniques in Mashhad, Iran. *Parasitol Res.* 2007; 100(6):1257–60.
14. Barr BC, Conrad PA, Dubey JP, Anderson ML. *Neospora*-like encephalomyelitis in a calf: pathology, ultrastructure, and immunoreactivity. *J Vet Diagn Invest.* 1991; 3: 310–46.
15. Gonzalez, L, Buxton D, Ataerandio R, Aduriz G, Maley S, Marco JC

- Cuervo LA. Bovine abortion associated with *Neospora caninum* in northern Spain. *Vet Rec.* 1999; 144:145–50.
16. Wouda W, Moen AR, Visser IJ, van Knapen DF. Bovine fetal neosporosis: a comparison of epizootic and sporadic abortion cases and different age classes with regard to lesion severity and immunohistochemical identification of organisms in brain, heart, and liver. *J Vet Diagn Investig.* 1997; 10:180–5.
 17. Gibney EH, Kipar A, Rosbottom A, Guy CS, Smith RF, Hetzel U, Trees AJ, Williams DJ. The extent of parasite-associated necrosis in the placenta and fetal tissues of cattle following *Neospora caninum* infection in early and late gestation correlates with fetal death. *Inter J Parasitol.* 2008; 38:579–88.
 18. Ortega-Mora LM, Fernández-García A, Gómez-Bautista M. Diagnosis of bovine neosporosis: Recent advances and perspectives. *Acta Parasitol.* 2006; 51(1), 1–14.
 19. Barr BC, Anderson ML, Blanchard PC, Daft BM; Kinde H; Conrad PA. Bovine fetal encephalitis and myocarditis associated with protozoal infections. *Vet Pathol.* 199-; 27:354–61.
 20. Nietfeld JC, Dubey JP, Anderson ML. *Neospora* like protozoan infection as a cause of abortion in dairy cattle. *J Vet Diagn Invest.* 1992; 4:223–6.
 21. Maxie MG, Jubb Kennedy and Palmer's Pathology of Domestic Animals, Academic Press, 5th edition, Saunders Elsevier, USA, Vol.1, 2007.
 22. Conrad PA, Sverlow K, Anderson M, Rowe J, BonDurant R, Tuter G, Breitmeyer R, Palmer C, Thurmond M, Ardans A, Dubey JP, Duhamel G, Barr B. Detection of serum antibody responses in cattle with natural or experimental *Neospora* infections. *J Vet Diagn Investig.* 1993; 5:572-578.
 23. Dubey JP, Lindsay DS. A review of *Neospora caninum* and neosporosis. *Vet Parasitol.* 1996; 67:1-59.
 24. Gottstein B, Hentrich B, Wyss R, Thur B, Busato A, Stark AD, Muller N.. Molecular and immunodiagnostic investigations on bovine neosporosis in Switzerland. *Int J Parasitol.* 1996;28:679-91.
 25. Baszler TV, Gay LJC, Long MT, Mathison BA. Detection by PCR of *Neospora caninum* in fetal tissues from spontaneous bovine abortions. *J Clin Microbiol.* 1999; 37: 4059–64.
 26. Sager H, Fischer I, Furrer K, Strasser M, Waldvogel A, Boerlin P, Audigé L, Gottstein B. A Swiss case-control study to assess *Neospora caninum* associated bovine abortions by PCR, histopathology and serology. *Vet Parasitol.* 2001; 102:1-15.
 27. Medina L, Cruz-Vazquez C, Quezada T, Morales E, Garcia-Vazquez Z. Survey of *Neospora caninum* infection by nested PCR in aborted fetuses from dairy farms in Aguascalientes, Mexico. *Vet Parasitol.* 2006;136:187-91.
 28. Maanen C van, Wouda W, Schares G, Blumröder D von, Conraths FJ, Norton R, Williams DJL, Esteban-Redondo I, Innes EA, Mattsson JG, Björkman C, Fernández-García A, Ortega-Mora LM, Muller N, Sager H, Hemphill A. An interlaboratory comparison of Immuno-histochemistry and PCR methods for detection of *Neospora caninum* in bovine foetal tissues. *Vet Parasitol.* 2004, 126, 351–64.
 29. Holmdahl OJM, Mattsson JG. Rapid and sensitive identification of *Neospora caninum* by in vitro amplifica-

- tion of the internal transcribed spacer 1. Parasitol. 1996; 112, 177–82.
30. Muller N, Zimmermann V, Hentrich B, Gottstein B. Diagnosis of *Neospora caninum* and *Toxoplasma gondii* infection by PCR and DNA hybridization immunoassay. J Clin Microbiol. 1996; 34:2850–52.
 31. Sadrebazzaz A, Haddadzadeh H, Esmailnia K, Habibi G, Vojgani M, Hashemifesharaki R. Serological prevalence of *Neospora caninum* in healthy and aborted dairy cattle in Mashhad, Iran. Vet Parasitol. 2004;124:201–4.
 32. Razmi GR, Mohammadi GR, Garrosi T, Farzaneh N, Fallah AH, Maleki M. Seroepidemiology of *Neospora caninum* infection in dairy cattle herds in Mashhad area, Iran. Vet Parasitol. 2006; 135:187–9.
 33. Malmasi A, Hosseinienejad M, Haddadzadeh H, Badii A, Bahonar A. Serological study of anti-*Neospora caninum* antibodies in household dogs and dogs living in dairy and beef cattle farms in Tehran, Iran. Parasitol Res. 2007; 100:1143–5.
 34. Haddadzadeh HR, Sadrebazzaz A, Malmasi A, Talei Ardakani A, Khazraii Nia P, Sadreshirazi N. Seroprevalence of *Neospora caninum* infection in dogs from rural and urban environments in Tehran, Iran. Parasitol Res. 2007; 101(6):1563-5.
 35. Razmi GR, Maleki M, Farzaneh N, Talebkhan Garoussi M, Fallah AH. First report of *Neospora caninum*-associated bovine abortion in Mashhad area, Iran. Parasitol Res. 2007; 100(4):755-7.
 36. Nourollahi Fard SR, Khalili M, Aminzadeh A. Prevalence of antibodies to *Neospora caninum* in
 44. Peter M, Lutkfels E, Heckerroth AR, Schares G. Immunohistochemical and cattle in Kerman province, South East Iran. Vet Arhiv. 2008; 78, 253-9.
 37. Luna LG. Manual of Histologic Staining Method of the Armed Force Institute of Pathology, 3rd edition, Mc Graw-Hill Book Company, New York, USA 1968.
 38. Gondim LF, McAllister MM, Anderson-Sprecker RC, Bjorkman C, Lock TF, Firkins LD, Gao L, Fischer, WR. Transplacental transmission and abortion in cows administered *Neospora caninum* oocysts. J Parasitol. 2004; 100, 1394–400.
 39. Barr BC, Conrad PA, Breitmeyer R, Sverlow K, Anderson ML, Reynolds J, Chauvet AE, Dubey JP, Ardans AA. Congenital *Neospora* infection in calves born from cows that had previously aborted *Neospora*-infected fetuses: four cases (1990– 1992). J Am Vet Med Assoc. 1993; 202:113–7.
 40. Shivaprasad HL, Ely R, Dubey JP. A *Neospora*-like protozoon found in an aborted bovine placenta. Vet Parasitol 1989; 34:145–8.
 41. Dubey JP, Buxton D, Wouda W. Pathogenesis of bovine neosporosis, J Comp Pathol. 2006; 134:267-89.
 42. Corbellini LG, Pescador CA, Frantz F, Wunder E, Steffen D, Smith DR, Drimeier D. Diagnostic survey of bovine abortion with special reference to *Neospora caninum* infection: importance, repeated abortion and concurrent infection in aborted fetuses in Southern Brazil Vet J. 2006; 172:114–20.
 43. Dubey JP, Leathers CW, Lindsay DS. *Neospora caninum*-like protozoan associated with fatal myelitis in newborn calves. J Parasitol. 1989; 75:146–8.
 43. ultrastructural evidence for *N. caninum* tissue cysts in skeletal mus-

- cles of naturally infected dogs and cattle. *Int J Parasitol.* 2001; 31:1144–8.
45. Morales E, Trigo FJ, Ibarra E, Puente E, Santacruz M. Neosporosis in Mexican dairy herds: lesions and immunohistochemical detection of *Neospora caninum* in fetuses. *J Comp Pathol.* 2001; 125:58–63.
46. Habibi GR, Hashemifesharaki R, Sadrebazzaz A, Bozorgi S, Bordbar N. Seminested PCR for diagnosis of *Neospora caninum* infection in cattle. *Arch Razi Ins.* 2005;59:55-64.
47. Jackson DP, Hayden JD, Quirk P. Extraction of nucleic acid from fresh and archival material. In: McPherson JJ, Quirk P, Taylor GR (eds) *PCR: a practical approach.* Oxford University Press, New York, NY, 1992; 29-50.