



Tehran University of Medical  
Sciences Publication  
<http://tums.ac.ir>

Iran J Parasitol

Open access Journal at  
<http://ijpa.tums.ac.ir>



Iranian Society of Parasitology  
<http://isp.tums.ac.ir>

## Original Article

# Assessment of the Scolicidal Effect of Bile: An *Ex Vivo* Study

Yahya Alperen Bayraktar <sup>1</sup>, Mehmet Ali Eryılmaz <sup>2</sup>, \*Mehmet Eşref Ulutaş <sup>3</sup>,  
Alpaslan Şahin <sup>2</sup>, Gürcan Şimşek <sup>2</sup>, Şerife Yüksekaya <sup>4</sup>

1. Aksaray Training and Research Hospital, General Surgery Department, Aksaray, Turkey
2. Department of General Surgery, University of Health Science, Konya City Hospital, Konya, Turkey
3. Department of General Surgery, University of Health Science, Gaziantep City Hospital, Gaziantep, Turkey
4. Department of Microbiology, University of Health Science, Konya City Hospital, Konya, Turkey

Received 19 Nov 2024  
Accepted 18 Jan 2025

**Keywords:**  
*Echinococcus granulosus*;  
Hydatid cyst;  
Bile;  
Scolicidal effect;  
Sheep

**\*Correspondence Email:**  
[esref\\_ulutas@hotmail.com](mailto:esref_ulutas@hotmail.com)

### Abstract

**Background:** Approximately 25% of hepatic hydatid cysts rupture into the biliary tract. The precise effect of bile within the cyst on protoscoleces remains unclear. We aimed to elucidate the effect of bile on protoscoleces.

**Methods:** The contents of hydatid cysts from the livers of three sheep were aspirated under sterile conditions. The aspirated contents were divided into 50 separate Eppendorf tubes (5 cc). Samples from each tube were stained with 0.1% eosin Y. Pink stained protoscoleces were considered dead under light microscopy (x100). A total of 100 protoscoleces were counted in each sample, and the number of live and dead protoscoleces was recorded. The tubes were randomly divided into five groups. Group 1 served as the control, Group 2 received normal saline (NS), Group 3, received hypertonic saline, Group 4 received bile, and Group 4 received diluted bile. The number of live and dead protoscoleces was recorded at the end of the first and second hours.

**Results:** Compared to the initial count of live protoscoleces, the number of live protoscoleces increased at hours 1 and 2 in Groups 2 and 4. No live protoscoleces remained at hours 1 and 2 in Group 3. There was no significant change in Group 5. When compared to the control group, a significant increase in viability was observed only in Group 4 ( $P=0.001$ ).

**Conclusion:** Bile of sheep does not exhibit scolicidal effects; rather, it positively affects protoscoleces by increasing viability.



Copyright © 2025 Alperen Bayraktar et al. Published by Tehran University of Medical Sciences.

This work is licensed under a Creative Commons Attribution-NonCommercial 4.0 International license.

(<https://creativecommons.org/licenses/by-nc/4.0/>). Non-commercial uses of the work are permitted, provided the original work is properly cited

DOI: [10.18502/ijpa.v20i1.18108](https://doi.org/10.18502/ijpa.v20i1.18108)

## Introduction

**A** hepatic hydatid cyst (HHC) is a zoonotic disease characterized by regional involvement caused by *Echinococcus granulosus*. It most commonly affects the liver and lungs, with liver involvement present in approximately two-thirds of cases (1). In 25% of HHC cases, clinical conditions such as biliary colic, cholangitis, and obstructive jaundice arise due to rupture into the biliary tract (2–4). Treatment for HHC includes medical, surgical, and interventional radiological methods (PAIR: percutaneous aspiration, injection of a scolicide, and reaspiration). Surgical treatment is generally required for cases of HHC associated with bile. Endoscopic retrograde cholangiopancreatography (ERCP) is also used in diagnosis and treatment. If clinical symptoms of obstructive jaundice and cholangitis are present, ERCP is strongly recommended (5).

The choice of scolicidal agent for the above mentioned treatments remains controversial. An ideal germicidal agent should have no toxic effects on the biliary tract, be effective on cystic vesicles, and have no systemic effects. Hydrogen peroxide, cetrimide, 20% hypertonic saline, 0.5% silver nitrate, chlorhexidine, 10% polyvidone iodine, and 70% alcohol are commonly used for this purpose. Among these, 20% hypertonic saline is the most frequently used. However, cases of sudden death associated with hydrogen peroxide use have been reported (6). Hyponatremia and sclerosing cholangitis have been documented with the use of hypertonic saline, and sclerosing cholangitis has been reported with alcohol use. Therefore, the use of scolicidal agents such as alcohol and hypertonic saline during PAIR is not appropriate if the hydatid cyst is opening into the biliary tract (7,8). Due to the lack of sufficient information in the literature

concerning the scolicidal effect of bile, surgical treatment is required even if ERCP is performed in bile related HHC. If bile were indeed scolicidal, ERCP alone could suffice as treatment, eliminating the need for surgical interventions.

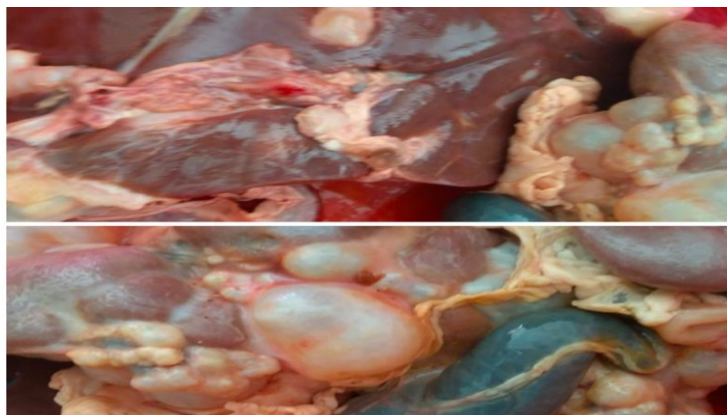
There is no consensus in the literature regarding a scolicidal agent that can safely be used in bile-related HHC cases. In clinical practice, there is a general belief that bile can be scolicidal. In a study where this theory was tested, chenodeoxycholic acid, a bile acid, was reported to induce apoptosis in protoscoleces (9). However, there is a scarcity of research in the existing literature investigating the effect of bile on protoscoleces. Therefore, we aimed to examine the effect of bile on protoscoleces.

## Materials and Methods

The research was carried out at the Microbiology Laboratory of Health Sciences University Konya City Hospital in Turkey.

The study was started after receiving local ethics committee approval (August 5, 2021/01-23).

The sheep livers utilized in the study were procured from the Karatay District Directorate of Agriculture under veterinary supervision (Fig. 1). Cyst contents were aspirated from three sheep livers with hydatid cysts using a syringe under sterile conditions. Concurrently, bile samples were obtained from the same sheep. In total, fluid was extracted from eight different cysts in three livers. Specimens with cystic fluid volumes below 10 cc were not included in the study. A cumulative volume of 100 cc of cystic fluid was collected. Both cystic fluids and bile samples were promptly transported to the laboratory within one hour at 0-4 °C under sterile conditions.



**Fig. 1:** Images of hydatid cysts in sheep livers

The cyst contents obtained from sheep were divided into two separate large Eppendorf tubes and allowed to stand for one day to achieve sedimentation. The supernatant portions were then separated. From the remaining portion (approximately 10 cc remained in each large Eppendorf tube), approximately 1 cc each was stained with eosin Y to assess the presence of viable protoscoleces. As viability was observed in more than 10% of the samples from both tubes, both tubes were included in the study. Portions of the precipitate remaining in the two large Eppendorf tubes were combined in another tube. Approximately 30 cc of additional supernatant was added to increase this 20 cc volume to 50 cc. As a result, a 50 cc mixture of precipitate and supernatant to be used in the study was obtained.

The resulting 50 cc solution was homogenized and divided into 50 separate 5 cc Eppendorf tubes. (Fig. 2-A,B,C,D) Each

tube was filled with 1 cc of homogenized cyst fluid. The following five groups were created, with 10 tubes allocated to each group:

Group 1: control

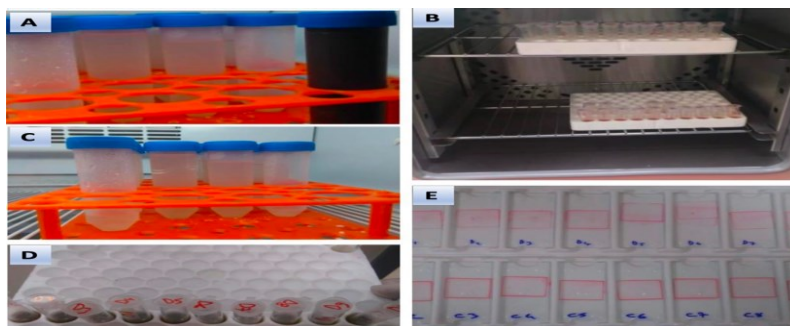
Group 2: normal saline (NS)

Group 3: hypertonic saline (HS)


Group 4: bile

Group 5: diluted (1/2) bile with NS

From each tube, 0.1 cc of fluid was extracted, and the staining procedure was conducted using 0.1 ml of 0.1% eosin Y solution (Fig. 2-E). Following staining, the tubes were incubated in an oven for five minutes at 37 °C. To ensure a homogeneous environment and the retrieval of equal amounts of cells from each tube, the tubes were vortexed to mix thoroughly. A total of 100 protoscoleces were counted. Protoscoleces exhibiting a pink coloration due to eosin Y staining were deemed dead (Fig. 3). The counts of live and dead protoscoleces were recorded for the 50 tubes.



**Fig. 2:** Images of the laboratory procedures performed



**Fig. 3:** Images of dead and live protoscoleces under a light microscope (x100)

Group 1: Ten tubes were kept in the oven (37 °C) without any intervention.

Group 2: To each of the ten tubes, 1 cc of NS was administered. Following this procedure, the tubes were kept in the oven (37 °C).

Group 3: To each of the ten tubes, 1 cc of HS (20%) was administered. Following this procedure, the tubes were kept in the oven (37 °C).

Group 4: To each of the ten tubes, 1 cc of undiluted bile obtained from sheep was administered. Following this procedure, the tubes were kept in the oven (37 °C).

Group 5: To each of the ten tubes, 0.5 cc of bile obtained from sheep was administered after dilution by 50% with NS. Following this procedure, the tubes were kept in the oven (37 °C).

Samples of 0.1 cc were extracted from all tubes at the end of the first and second hours and subjected to staining procedures. Live and dead protoscoleces were counted under a light microscope and recorded.

Prior to commencing statistical analysis, the Kolmogorov-Smirnov and Shapiro-Wilk tests were conducted to assess normality. In cases where normality could not be achieved in any of the groups, non-parametric methods were employed. The analysis of variance (ANOVA) test was performed for multiple group comparisons. The Bonferroni and Tamhane-T2

tests were used based on the homogeneity or non-homogeneity of variances, respectively. The repeated measures ANOVA was conducted to assess changes in the proportions of live protoscoleces within groups. Quantitative variables were presented as mean (standard deviation) values. Statistical analysis was conducted using the Statistical Package for the Social Sciences (SPSS), version 22.0 (IBM Corp., Armonk, NY, USA), and a significance level of  $P < 0.05$  was considered statistically significant.

## Results

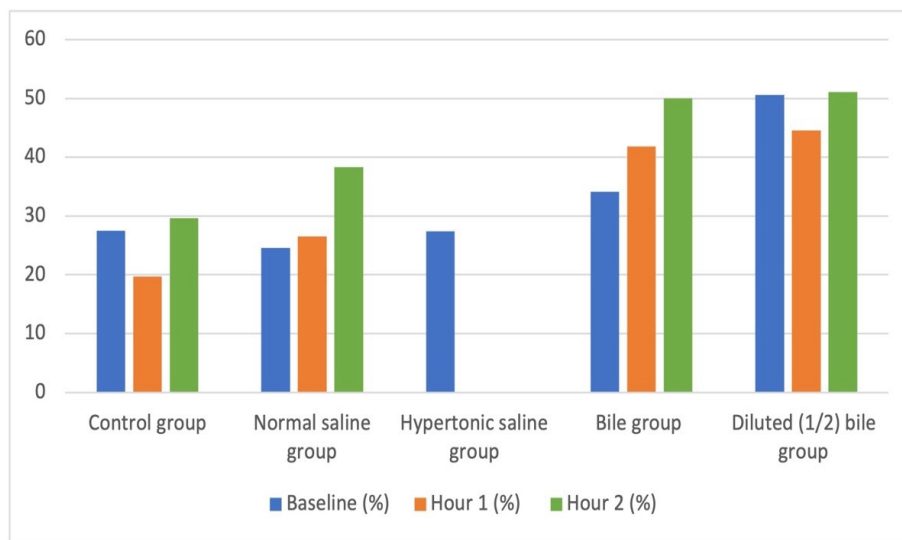
In Group 1, the mean number of live protoscoleces at baseline was 27.5 ( $\pm 12.7$ ), decreasing to 19.7 ( $\pm 9$ ) at hour 1 and increasing to 29.6 ( $\pm 8.3$ ) at hour 2. Group 2 exhibited an initial mean count of live protoscoleces of 24.6 ( $\pm 10.5$ ), which increased to 26.5 ( $\pm 10.2$ ) at hour 1 and further to 38.3 ( $\pm 10.5$ ) at hour 2. In Group 3, the initial count of live protoscoleces was 27.4 ( $\pm 11.6$ ), with no live protoscoleces remaining at hours 1 and 2. Group 4 displayed an initial count of live protoscoleces of 34.1 ( $\pm 14.8$ ), increasing to 41.8 ( $\pm 7.8$ ) at hour 1 and to 50 ( $\pm 8.8$ ) at hour 2. In Group 5, the baseline count of live protoscoleces was 50.6 ( $\pm 4.5$ ), decreasing to 44.5 ( $\pm 8.3$ ) at hour 1 and then increasing to 51.1 ( $\pm 8.4$ ) at hour 2 (Table 1 and Fig. 4).

**Table 1:** Comparison of live protoscolex percentages between the groups

	Group 1	Group 2	Group 3	Group 4	Group 5	P
<b>Baseline</b>	27.5 ± 12.7 <sup>a</sup>	24.6 ± 10.5 <sup>b</sup>	27.4 ± 11.6 <sup>c</sup>	34.1 ± 14.8	50.6 ± 4.5 <sup>a,b,c</sup>	<0.001
<b>Hour 1</b>	19.7 ± 9 <sup>a,b,c</sup>	26.5 ± 10.2 <sup>d,e</sup>	0 <sup>a,d,f,g</sup>	41.8 ± 7.8 <sup>b,f</sup>	44.5 ± 8.3 <sup>c,e,g</sup>	<0.001
<b>Hour 2</b>	29.6 ± 8.3 <sup>a,b,c</sup>	38.3 ± 10.5 <sup>d</sup>	0 <sup>a,d,e,f</sup>	50 ± 8.8 <sup>b,e</sup>	51.1 ± 8.4 <sup>c,f</sup>	<0.001

Each identical superscript (<sup>a-g</sup>) denotes subsets within group categories that differ significantly from each other at the  $P < 0.05$  level.

Group 1: control, Group 2: normal saline, Group 3: hypertonic saline, Group 4: bile, Group 5: diluted (1/2) bile



**Fig. 4:** Distribution of live protoscolex percentages by group and time

Upon examination of the initial counts of live protoscolexes, the highest value was observed in Group 5 ( $50.6 \pm 4.5$ ). The number of live protoscolexes in Group 5 was significantly higher than in Groups 1, 2, and 3 ( $P < 0.001$ ).

At hour 1, the highest count of live protoscolexes was observed in Group 5 ( $44.5 \pm 8.3$ ), and the lowest count was in Group 3 (0). The number of live protoscolexes in Group 5 was significantly higher than in Groups 1, 2, and 3 ( $P < 0.001$ ). Group 4 exhibited a significantly higher number of live protoscolexes than Groups 1 and 3 ( $P < 0.001$ ). The number of live protoscolexes in Group 2 was higher than in Group 3 ( $P < 0.001$ ) (Table 1).

At hour 2, the highest count of live protoscolexes was detected in Group 5 ( $51.1 \pm 8.4$ ), while Group 3 had no live protoscolexes. The number of live protoscolexes in Group 5 was significantly higher than in Groups 1 and 3 ( $P < 0.001$ ). Group 4 exhibited a higher number of live protoscolexes than Groups 1 and 3 ( $P < 0.001$ ). The number of live protoscolexes was higher in Group 2 than in Group 3 ( $P < 0.001$ ), and it was also higher in Group 1 than in Group 3 ( $P < 0.001$ ) (Table 1).

In Group 2, the number of live protoscolexes increased over time ( $P = 0.05$ ). In Group 3, no live protoscolexes were observed at hours 1 and 2 ( $P < 0.001$ ). In Group 4, the number of live protoscolexes increased over time ( $P =$



0.03). In Group 5, there was no significant change in the number of live protoscolexes

over time ( $P = 0.05$ ) (Table 2).

**Table 2:** Evaluation of live protoscolex percentages within each group according to time

	Baseline	Hour 1	Hour 2	P
<b>Group 1</b>	27.5 ± 12.7	19.7 ± 9	29.6 ± 8.3	0.19
<b>Group 2</b>	24.6 ± 10.5	26.5 ± 10.2	38.3 ± 10.5	0.05
<b>Group 3</b>	27.4 ± 11.6	0	0	<0.001
<b>Group 4</b>	34.1 ± 14.8	41.8 ± 7.8 <sup>a</sup>	50 ± 8.8 <sup>a</sup>	0.03
<b>Group 5</b>	50.6 ± 4.5	44.5 ± 8.3	51.1 ± 8.4	0.05

Each identical superscript (<sup>a</sup>) denotes subsets within group categories that differ significantly from each other at the  $P < 0.05$  level. Group

## Discussion

For years, the quest for a potent yet minimally adverse scolicidal agent has persisted. Substances such as polyvidoneiodine, ethyl alcohol, silver nitrate, and HS are among the first that were utilized. Among these, HS remains the most effective and commonly used agent to date. However, it is recognized that all these agents carry varying degrees of biliary toxicity (6-8). Therefore, the search continues for less toxic agents.

In a previous study, Kismet et al. demonstrated the scolicidal effect of propolis in rats (10). Kılıçoğlu et al. examined the effect of honey, proven to have a scolicidal effect in rats, on the biliary system, concluding that it was safe in rats (11). The combined use of gold nanoparticles and lasers had a scolicidal effect (12). Rahimi et al. demonstrated the partial scolicidal effect of silver nanoparticles (13). Amphotericin B with silver nanoparticles had weak scolicidal effects, whereas *Foeniculum vulgare* (fennel) showed strong scolicidal effects (14). *Allium sativum* (garlic) extract has also been investigated in terms of its scolicidal effects and found effective (15). In vitro study, Moazeni et al. demonstrated the scolicidal effect of warm water (16). All of these studies were conducted in experimental settings or on animals, with the results of none being sup-

ported by clinical trials or adopted into clinical practice.

ported by clinical trials or adopted into clinical practice.

ported by clinical trials or adopted into clinical practice.

ported by clinical trials or adopted into clinical practice.

ported by clinical trials or adopted into clinical practice.

may exert a scolicial effect similar to HS on protoscoleces. In one study, Shi et al. indicated that CDCA in bile induced apoptosis in protoscoleces. However, apart from that study, no experimental or *Ex Vivo* studies investigating the effect of bile on protoscoleces have been found in the literature. Contrary to the findings of that study, we found that bile did not have a scolicial effect. In fact, statistically significant increases were observed in the viability of protoscoleces following the administration of bile compared to the other substances tested.

In experimental studies such as ours, maintaining the viability of parasites is challenging, as numerous factors can contribute to protoscolex death. These include the eosin stain itself, dilution with water, and inappropriate storage conditions of the preparations. In our study, dilution with NS and incubation at 37 °C were employed to mimic in vivo conditions as closely as possible.

One limitation of our study is that the composition of the bile used was not thoroughly examined. Different densities or contents of bile may have different effects. Particularly, the ratio and amount of bile acids may lead to different results. Future studies utilizing bile samples with similar densities and contents are warranted to minimize this effect. Another limitation is the use of both animal cyst contents and animal bile in our study. Studies using samples obtained from human hydatid cysts and bile would have higher clinical relevance.

## Conclusion

Our study is the first to investigate the effect of bile on protoscoleces. The key findings of this study indicate that the general belief among clinicians regarding the scolicial effect of bile is inaccurate, and the existing literature on this topic is insufficient. Further studies examining bile content in more detail and focusing on isolated bile acids are needed.

## Conflict of Interest

The authors declare that there is no conflict of interests.

## References

1. Wen H, Vuitton L, Tuxun T, et al. Echinococcosis: advances in the 21st century. *Clin Microbiol Rev.* 2019; 32(2): e00075-18.
2. Bektaş M, Dökmeçi A, Cınar K, et al. Endoscopic management of biliary parasitic diseases. *Dig Dis Sci.* 2010; 55: 1472-78.
3. Khuroo MS, Zargar SA, Mahajan R. *Echinococcus granulosus* cysts in the liver: management with percutaneous drainage. *Radiology.* 1991; 180(1): 141-5.
4. Akhan O, Özmen MN, Dinçer A, Sayek I, Göçmen A. Liver hydatid disease: long-term results of percutaneous treatment. *Radiology.* 1996; 198(1): 259-64.
5. Kayaalp C, Bostancı B, Yol S, Akoglu M. Distribution of hydatid cysts into the liver with reference to cystobiliary communications and cavity-related complications. *Am J Surg.* 2003;185(2):175-9.
6. Balkan M, Balkan A, Kilciler G, Menten O, Aydın A, Oner K. The evaluation of the effects of cetrimide-chlorhexidine and hypertonic sodium chloride combination on liver, lung, and biliary tract in hydatid disease. *Balkan Military Medical Review.* 2007; 10: 127-131.
7. Arikoglu H. Histologic evaluation of the efficacy of different scolicial agents on the viability of scolices. Postgraduate thesis Selçuk University. 1996;53.
8. Abbas A, Shadmehr B, Ghaffarinejat MH, Shishineh P, Saidi F. Scolicial agents can cause sclerosing cholangitis. *London J Hepatic Pancreatic Biliary Surg.* 1990;2:157.
9. Shi H, Lei Y, Wang B, et al. Protoscolicial effects of chenodeoxycholic acid on protoscoleces of *Echinococcus granulosus*. *Exp Parasitol.* 2016;167:76-82.
10. Kismet K, Kilicoglu B, Koru O, et al. Evaluation on scolicial efficacy of propolis. *Eur Surg Res.* 2006;38(5):476-81.

11. Kilicoglu B, Kismet K, Kilicoglu SS, et al. Effects of honey as a scolicidal agent on the hepatobiliary system. *World J Gastroenterol.* 2008;14(13):2085–8.
12. Çolak B, Aksoy F, Yavuz S, Demircili ME. Investigating the effect of gold nanoparticles on hydatid cyst protoscolices under low-power green laser irradiation. *Turk J Surg.* 2019;35(4):314–20.
13. Rahimi MT, Ahmadpour E, Rahimi Esboei B, et al. Scolicidal activity of biosynthesized silver nanoparticles against *Echinococcus granulosus* protoscolices. *Int J Surg.* 2015; 19:128–33.
14. Lashkarizadeh MR, Asgaripour K, Saedi Dezaki E, Fasihi Harandi M. Comparison of Scolicidal Effects of Amphotricin B, Silver Nanoparticles, and *Foeniculum vulgare* Mill on Hydatid Cysts Protoscolices. *Iran J Parasitol.* 2015;10(2):206-12.
15. Moazeni M, Nazer A. In vitro effectiveness of garlic (*Allium sativum*) extract on scolices of hydatid cyst. *World J Surg.* 2010;34(11):2677–81.
16. Moazeni M, Alipour-Chaharmahali MR. *Echinococcus granulosus*: in vitro effectiveness of warm water on protoscolices. *Exp Parasitol.* 2011;127(1):14–7.
17. Perez MJ, Britz O. Bile-acid-induced cell injury and protection. *World J Gastroenterol.* 2009;15(14):1677-89.
18. Martinez JD, Stratagoules ED, LaRue JM, et al. Different bile acids exhibit distinct biological effects: the tumor promoter deoxycholic acid induces apoptosis and the chemopreventive agent ursodeoxycholic acid inhibits cell proliferation. *Nutr Cancer.* 1998;31(2):111-8.
19. Bernstein C, Bernstein H, Garewal H, et al. A bile acid-induced apoptosis assay for colon cancer risk and associated quality control studies. *Cancer Res.* 1999;59(10):2353-7.
20. Musikant D, Leverrier A, Bernal D, Ferri G, Palermo JA, Edreira MM. Hybrids of Cinchona Alkaloids and Bile Acids as Antiparasitic Agents Against *Trypanosoma cruzi*. *Molecules.* 2019;24(17):3168.
21. Floch MH, Binder HJ, Filburn B, Gershengoren W. The effect of bile acids on intestinal microflora. *Am J Clin Nutr.* 1972;25(12):1418–26.
22. Merritt ME, Donaldson JR. Effect of bile salts on the DNA and membrane integrity of enteric bacteria. *J Med Microbiol.* 2009; 58(Pt 12):1533-1541.