



Tehran University of Medical
Sciences Publication
<http://tums.ac.ir>

Iran J Parasitol

Open access Journal at
<http://ijpa.tums.ac.ir>



Iranian Society of Parasitology
<http://isp.tums.ac.ir>

Original Article

Clinical, Morphological Justification and First Experience in the Use of Radiofrequency as well as Microwave Ablation Treatment Methods of Liver Echinococcosis

Alexey Shabunin ^{1,2}, *Alexey Karpov ¹, Vladimir Bedin ^{1,2}, Mikhail Tavobilov ^{1,2}, Grigory Checenin ^{1,2}, Sergey Lebedev ^{1,2}, Natalya Ivanova ¹, Anatoliy Malishev ¹, Mark Aladin ², Kirill Abramov ¹

1. Botkin Hospital, Moscow Healthcare Department, Moscow, Russian Federation
2. Department of Surgery, Russian Medical Academy, Continuing Professional Education, Ministry of Health, Moscow, Russian Federation

<p>Received 20 Aug 2022 Accepted 16 Nov 2022</p>	<p>Abstract Background: The current study considers a new direction of surgical treatment of liver echinococcosis - the use of minimally invasive treatment methods of parasitic cysts. Methods: After clinical and morphological substantiation of the very possibility of carrying out such procedures, 9 microwave ablations (MWA) and 3 radiofrequency ablations (RFA) of cysts were performed in patients with liver echinococcosis from 2017 to 2021 in the surgical clinic of Botkin Hospital, Moscow, Russia. A comparative analysis of treatment results of patients with echinococcal liver cysts (12 patients who underwent “percutaneous puncture, aspiration, injection and reaspiration” (PAIR) procedure and 12 patients – MWA and RFA) was carried out. Results: The number of complications according to Clavien-Dindo classification was as follows: 8 after PAIR procedure, 3 after RFA and 3 after MWA. The median hospital length of stay (LOS) after PAIR procedure was 6.46 days versus 4.7 and 4 in the groups of patients who underwent RF and MW ablation, respectively. The frequency of relapses within the first year after PAIR procedure was 25%. The patients who underwent ablation procedures had no relapses of liver echinococcosis during observation. Conclusion: The presented clinical and morphological substantiation and the experience of using various types of ablation techniques on echinococcal cysts, as well as a comparative analysis with a commonly used PAIR treatment method, demonstrated the safety of RFA and MWA for the patient and efficacy in relation to the hydatid process.</p>
<p>Keywords: Hydatid cyst; Percutaneous puncture; Aspiration; Parasitology</p>	
<p>*Correspondence Email: botkin.karpov@yandex.ru</p>	



Introduction

Modern trends in medicine, the transition to minimally invasive methods of treatment in all surgical fields led to the development of minimally invasive techniques in surgery of patients with liver echinococcosis (1).

To date, the "golden" standard of surgery in patients with echinococcal liver cysts is liver resection and pericystectomy (2). There are several variants of minimally invasive treatment options of patients with liver echinococcosis - laparoscopic, robotic interventions and percutaneous-transhepatic drainage techniques (3). In recent years, techniques similar to PAIR (percutaneous puncture, aspiration, injection and reaspiration) and PEVAC (percutaneous evacuation) have become widespread, however, due to unsatisfactory results the search for new options for surgical treatment of the parasite is necessary (4).

With the accumulation of experience in the use of ablation treatment methods of malignant liver tumors, a positive assessment of the immediate and long-term results of their use led us to consider the possibility of using ablation treatment methods for patients with liver echinococcosis. Therefore, this study is devoted to this new direction in surgical treatment of parasitic liver diseases.

Materials and Methods

In the surgical clinic of Botkin Hospital, Moscow, Russia (onwards: clinic) during the period from 2007 to 2021, 301 patients with echinococcal liver disease have been treated. Unique feature of the clinic was the ability to implement all available options for surgical treatment: from minimally invasive percutaneous techniques to extensive liver resections, laparoscopic and robotic operations (5). The clinic has started using PAIR technique since 2017 (12 patients). After analyzing the results of using this modern percutaneous method,

we noted several complications such as supuration of the cyst cavity and relapses during the first year after the intervention. These results necessitated the search for new minimally invasive methods of surgical treatment of patients with echinococcal liver cysts.

Based on the colossal experience of Botkin Hospital in the treatment of patients with primary and secondary oncological diseases of the liver (more than 3000 patients), 330 of whom underwent tumor ablation procedures, we launched a clinical trial. The first stage of the study was clinical and morphological substantiation of both – the possibility of execution and the effectiveness of ablation methods in treatment of patients with echinococcal liver disease.

The first step was performing MWA and RFA of 27 removed echinococcal cysts *in vitro* and examining the results and after *in vivo* procedure (n=5), followed by complete removal of echinococcal cysts using open resection. The main aspects of result evaluation were:

- The safety of the technique,
- Morphological changes in the cyst wall,
- Cytological assessment of effectiveness of the ablation procedure.

The next part of the study evaluated the immediate and long-term results of PAIR technique, radiofrequency and microwave ablation (12 PAIR, 3 RFA and 9 MWA) in patients with echinococcal liver disease.

The indications for minimally invasive treatment methods were:

- intraparenchymal location of echinococcal cyst;
- Stage CE1-CE3a according to WHO-IGWE;
- PAIR: cyst size ranging from 5 to 10 cm;
- MWA & MFA: cyst size up to 12 cm.

Contraindications were:

- Multiple cysts in the liver;
- High ASA class (IV or higher).

The present study was approved in 2017 by the local Ethics Committee of the Botkin hospital. All participants signed written consent and the records of study participants were anonymized.

The following parameters were analyzed in this study: duration of the intervention, post-operative complications according to Clavien-Dindo classification, hospital length of stay, relapse during the first year after surgery (6).

Surgical procedures

PAIR technique in patients with liver echinococcosis.

The surgical clinic of Botkin Hospital has been using PAIR as a method of treatment of echinococcal cysts since 2017. The procedure was performed in an X-ray operating room under general anesthesia due to a potential risk of an anaphylactic reaction. The placed drain tube was removed the next day after conducting cytological examination of the cyst fluid for the presence of echinococcal parasite. In cases of verification of the presence of a living parasite, the procedure was repeated.

Microwave ablation of echinococcal cysts in patients with liver echinococcosis

The procedure was performed under general anesthesia in an X-ray operating room. The procedure was carried out with a microwave ablation system with a water-cooled antenna (a 60 W generator with an oscillation frequency of up to 2.45 GHz). The cyst was punctured under ultrasound guidance. A port was installed in the cyst, through which, if necessary, part of the hydatid fluid was evacuated. Before removal of liquid contents of the cyst, a microwave antenna was installed in the cavity. The exposure time was 6-7 minutes at a maximum output power on the antenna (50 watts). The antenna needle was removed from the liver parenchyma slowly during the remaining 20 seconds of the procedure, allowing the hot needle to coagulate the puncture channel, which prevented postoperative hemorrhage and parasitic dissemination.

Radiofrequency ablation of echinococcal cysts in patients with liver echinococcosis

The procedure was performed under general anesthesia in an X-ray operating room. The position of the patient on the operating table, similarly to the microwave technique, was determined by the localization of the cyst and the presence of an ultrasound acoustic window for a safe trajectory of the puncture needle and subsequently inserted electrode. The procedure was carried out using a radiofrequency ablation system with a set of electrodes (a 200 W generator with an oscillation frequency of 480 kHz). The cyst was punctured under ultrasound guidance. Parallel to the RFA electrode, a puncture needle with an adequate diameter for the evacuation of liquid contents of the cyst was inserted into the cyst. After the end of the procedure a drain is left in the cavity in order to control the effectiveness of the procedure and prevent possible complications.

The exposure time was 12 minutes. Similar to the MWA procedure, the electrode was removed from the liver parenchyma slowly in manual mode at maximum power, achieving heat treatment of the puncture channel, thus preventing postoperative hemorrhage and parasitic dissemination.

Postoperative observation

After the procedure the patient is transferred to the ward. Blood tests are performed 4 hours post operation. Intravenous infusion is carried out in the postoperative period including antibiotic prophylaxis. Ultrasound examination is performed on the first postoperative day. CT scan or MRI were performed on the second day to determine the efficacy of the ablation procedure and identify possible complications of the intervention

Statistical analysis

Statistical analysis was performed using SPSS v.23.0 (IBM Corp., Armonk, NY). Continuous data were presented as mean \pm SD

and analyzed using either Student's *t* test. Categorical data were compared using a Pearson χ^2 test or Fisher's exact test. A two-tailed $P < 0.05$ was considered statistically significant.

Results

Morphological evidence of the efficacy of ablation methods in patients with liver echinococcosis.

The majority of patients (19/24) (Fig. 1) had CE1 and CE3a cysts.

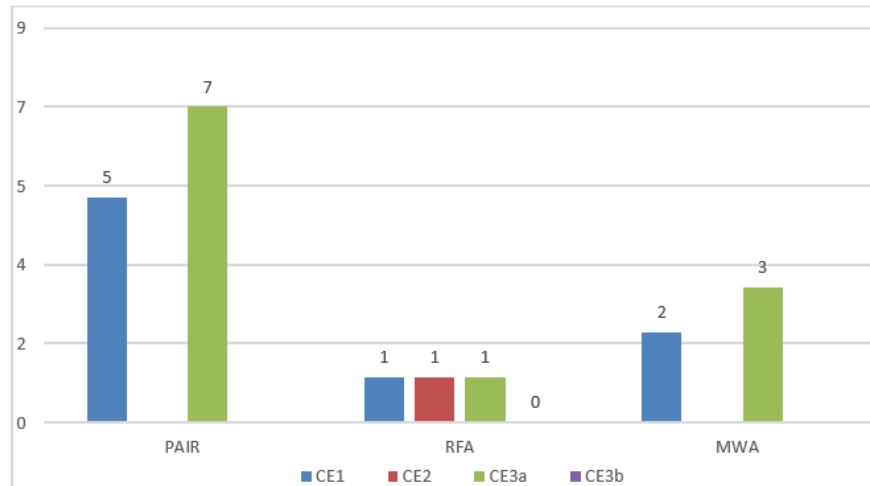


Fig. 1: Patient distribution (grouped by treatment method) by the class of the echinococcal cysts (WHO-IGWE)

In the group of patients who underwent RFA and MWA, cysts were predominantly sized from 5 to 10 cm, however, in two cases

the cyst size was less than 5 cm and in one case more than 10 cm (Fig. 2).

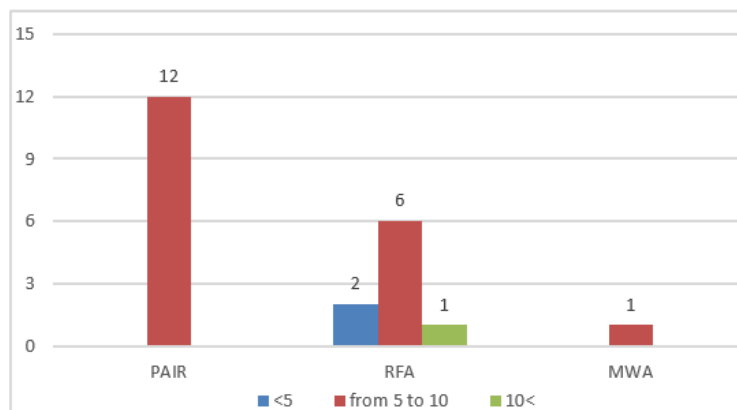


Fig. 2: Patient distribution by echinococcal cyst size in centimeters

Leakage of hydatid fluid parallel to the aspiration cannula and the electrode canal, was

noted only in 3 out of 27 cases (Table 1). Following changes were noted at microscopic

level after the procedure: the presence of a pronounced layer of necrosis in 26/27 cases, a significant decrease in the hyaline layer in 20/27 and degenerative changes in the chitin membrane in 21/27 (Fig. 3, 4).

In 5 cases, with a thorough cytological examination, we identified living echinococcal parasites (Fig. 5). These findings were associated with the insufficient duration of the procedure (~ 5 minutes) and the large size of the cysts (13-17 cm).

Table 1: Morphological and cytological evaluation after *in vitro* ablation of echinococcal cysts

<i>Variable</i>	<i>RFA (n=13)</i>	<i>MWA (n=14)</i>
Leakage of hydatid fluid	1	2
Violation of the integrity of the cyst	0	0
Destruction of large vessels	0	0
Destruction of large bile ducts	0	0
Presence of necrosed layer of liver parenchyma	12	14
Significant reduction of the hyaline layer	9	11
Dystrophic changes in the chitinous membrane	8	13
Presence of living echinococcal parasite in the cyst fluid	3	2

RFA = radiofrequency ablation, MWA = microwave ablation

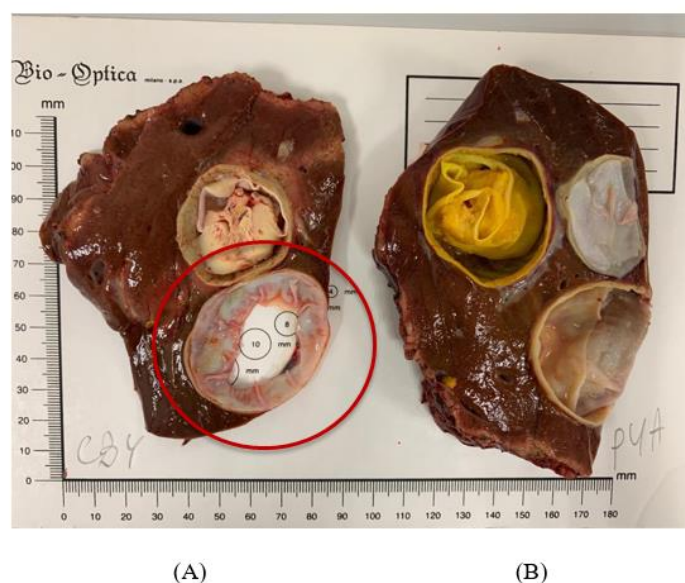


Fig. 3: Liver specimen after MW and RF ablation of the echinococcal liver cysts (image courtesy of Botkin Hospital).

(A) Pronounced coagulation changes after MWA. (B) Incomplete coagulation necrosis after RFA

After microwave ablation a 5 mm zone of inflammation around the wall of the echinococcal cyst is visualized at a macroscopic level.

The cyst after RF ablation showed signs of incomplete coagulation necrosis and residual hydatid fluid (Fig. 3B).

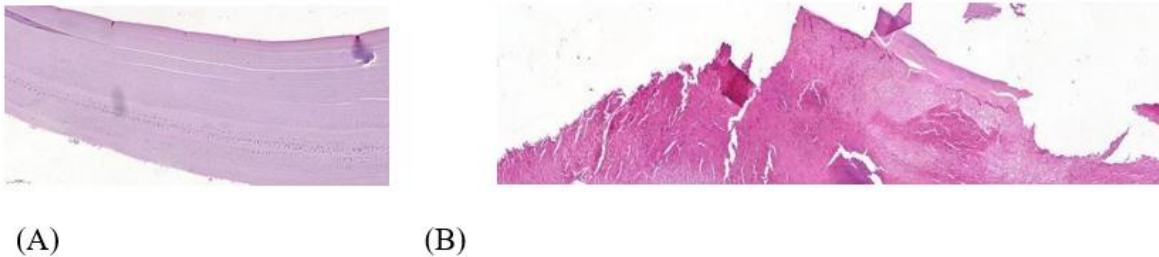


Fig. 4: Microscopic view of the cyst wall (images courtesy of Botkin Hospital)

(A) Unchanged echinococcal cyst wall (B) Evident necrobiotic changes in the chitinous membrane after microwave ablation

Pronounced destruction of the chitinous membrane is noted at microscopic level when comparing the wall of an unchanged echino-

coccal cyst and the chitinous membrane after microwave ablation.

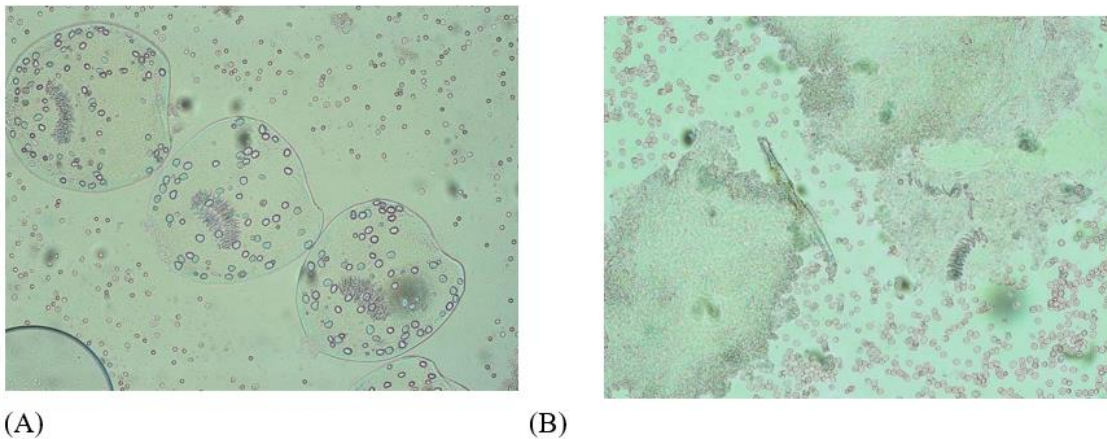


Fig. 5: Cytological examination of the hydatid fluid (image courtesy of Botkin Hospital)

(A) Unchanged echinococcal parasites after an ineffective RF ablation (B) Evident destruction of protoscolices after microwave ablation

Thus, in order to achieve effective results from the interventions, at this stage of the study, we excluded both cysts larger than 10 cm and standardized the time interval for RF and microwave ablation (11-12 and 6-7 minutes, respectively).

The next step of the research was analysis of effects of ablation treatment methods on liver

echinococcal cysts in five patients who underwent surgery as the second stage of treatment. All patients in this group underwent laparotomy, pericystectomy. The main points of evaluation were morphological and cytological changes in the wall and contents of the cysts (Table 2).

Table 2: Morphological and cytological evaluation after *in vivo* ablation of echinococcal cysts

<i>Variable</i>	<i>RFA (n=2)</i>	<i>MWA (n=3)</i>
Violation of cyst integrity	0	0
Destruction of large vessels	0	0
Destruction of large bile ducts	0	0
Presence of necrosed layer of liver parenchyma	2	3
Significant reduction of the hyaline layer	2	3
Dystrophic changes in the chitinous membrane	2	3
Presence of alive <i>Echinococcus</i> parasites	0	0
Full-blooded capillaries	2	3
Dilated lymphatic capillaries	2	3

RFA = radiofrequency ablation, MWA = microwave ablation

Effectiveness of ablation interventions in this group of patients was significantly higher than in the *in vitro* group (Table 2). This is attributed to smaller size of ablated cysts and

active inflammation in the post-procedure area, which, apparently, contributed to the improvement in the effectiveness of the procedure (Fig. 6).

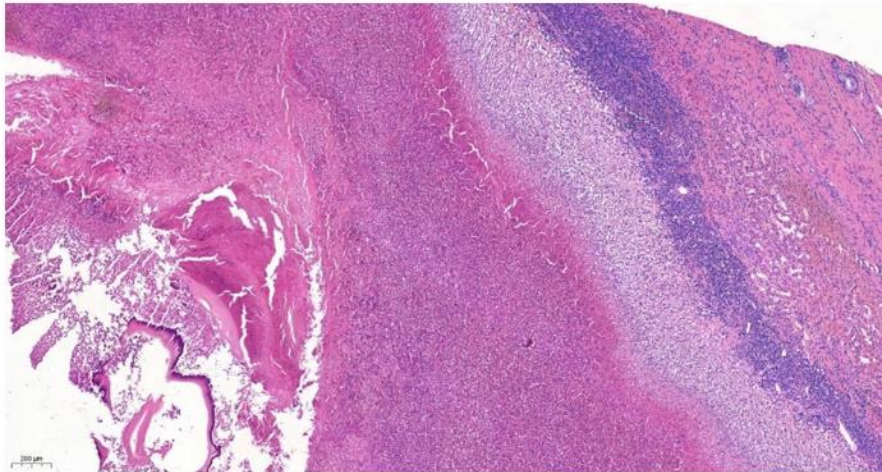


Fig. 6: Evident necrobiotic changes in the chitinous membrane after microwave ablation (image courtesy of Botkin Hospital) many capillaries, lymphatic vessels

Clinical substantiation of efficacy of echinococcal cysts ablation treatment methods.

In this part of our study we analyzed the immediate and long-term results of treatment of patients (n=24) with echinococcal liver dis-

ease who underwent various minimally invasive interventions: 12 PAIR procedures, 9 microwave ablations and 3 RF ablations of echinococcal cysts.

The duration of the intervention, postoperative complications (Clavien-Dindo), hospital

length of stay, the necessity for a repeat procedure and relapse during the first year after surgery were assessed.

Comparison of the immediate and long-term results of the use of PAIR, RFA and MWA treatment methods can be seen in Table 3.

Table 3: Immediate and long-term treatment results of patients after PAIR, RFA and MWA of echinococcal cysts

<i>Variable</i>	<i>PAIR (n=12)</i>	<i>RFA (n=3)</i>	<i>MWA (n=9)</i>	<i>p</i>
Operation duration	36 (31-44) min	42 (41-43) min	36,8 (29-47) min	0.166
Clavien-Dindo				
I	2	1	1	
II	2	2	0	
III	4	0	1	
IV	0	0	1	
V	0	0	0	
Total	8	3	3	0.156
LOS	6.46 (4-11)	4.7 (3-7)	4 (2-7)	0.063
Repeat treatment	4	0	0	0.100
Relapses during 12-month postoperative period	3/12 (25%)	0	0	0.193

PAIR = puncture, aspiration, injection, reaspiration, RFA = radiofrequency ablation, MWA = microwave ablation, LOS = hospital length of stay

The amount of Clavien-Dindo complications in the group of patients who underwent the PAIR method was 8 out of 12 patients, 4 complications were classified as class III and above, which required minimally invasive operations such as drainage of the residual cavity (Table 3). Three complications were recorded in the groups of patients after RFA and MWA. In one patient, after microwave ablation, a class III complication was noted, which required drainage of the residual cavity due to its initially large size (more than 10 cm). In one case, a patient after microwave ablation in the postoperative period experienced anaphylaxis, which required a transfer to the intensive care unit.

The duration of the postoperative hospital stay after PAIR was 6.46 versus 4.7 and 4 in the groups of patients who underwent RFA and MWA, respectively ($P=0.063$). The statistically longer hospital stay of patients after PAIR was due to postoperative complications, as well as repeated interventions in order to achieve necessary results. After performing a CT-scan or an MRI of the abdomen, the effi-

cacy of the procedure was confirmed, which allowed the patient to be discharged from the hospital.

Relapses during the first year after the PAIR procedure were 25%, which required other types of surgical treatment (pericystectomy or microwave ablation). In patients who underwent ablation treatment methods of echinococcal cysts, no relapses of the parasitic process in the liver were noted during the specified time.

Discussion

Currently, the treatment of liver echinococcosis is based on the recommendations of the WHO working group (7). Based on imaging data and in accordance with the stage of the disease, various treatment options are available: surgical treatment (total or subtotal pericystectomy, atypical and anatomic liver resection), PAIR (puncture, aspiration, injection, reaspiration) or its analogues, solo drug treatment or in a combination with other methods and a "watch-and-wait" approach.

The proposed algorithm for treatment of liver echinococcosis, according to the above classification, applies that PAIR procedure be used for type CE1 (single cyst) and CE3A (cyst with exfoliated chitinous membrane) in the absence of a cystobiliary communication (CBC). In CE2 (multilocular cyst) and CE3B (cyst with daughter cysts and cyst with solid contents) cysts, the PAIR technique or surgical treatment is used; for type CE4 (cyst with heterogeneous contents) and CE5 (solid cyst with calcifications) surgical treatment is not required. However, in the presence of complications (cystobiliary fistula, suppuration), various treatment options are available (8).

Even in modern times, the choice of treatment of liver echinococcosis often depends on experience of the surgeon and the availability of the necessary equipment, and to a lesser extent, on the type of cyst and its complications that have developed (9).

The surgical tactic, as a rule, depends on the experience of treating this certain category of patients in a particular clinic. Also most of the clinics dealing with this problem present a treatment analysis of a small number of observations. This is due to a rather low frequency of surgical operations performed for this pathology (10-12).

Last decade has seen the introduction of modern minimally invasive technologies such as PAIR (13). This technique allows to achieve comparable long-term results with a significantly low number of general and specific complications (5).

The main factor that contributed to the initiation of this fundamental research was the unsatisfactory results of PAIR treatment method. In the surgical clinic of Botkin Hospital we never encounter relapses after surgical operations, even over a long period of observation, compared to the time period after the introduction of PAIR. We noted a relapse of the disease in 25% of patients due to ineffectiveness of the procedure. This fact determined the need to search for new ways of sur-

gical treatment of patients with liver echinococcosis.

The fundamental basis for the clinical and morphological substantiation of the possibility of using ablation technologies in patients with liver echinococcosis was the colossal clinical experience and studies previously conducted in the clinic, which proved the effectiveness of applying ablation methods of treatment on primary and secondary liver tumors.

These morphological and clinical results allowed us to proceed to the next stage of the study - *in vitro* and *in vivo* MWA and RFA of echinococcal cysts. In order to assess the safety and effectiveness of these techniques in patients with echinococcal liver cysts, we performed 27 *in vitro* interventions. Together with the pathomorphological department of Botkin hospital, all cyst samples after ablation were examined at microscopic level and the following changes were noted: the presence of a pronounced layer of necrosis in 26/27 cases, a significant decrease in the hyaline layer in 20/27 cases and degenerative changes in the chitinous membrane in 21/27 cysts.

Complete destruction was not achieved in 5 patients: a thorough cytological examination revealed alive echinococcal parasites. These findings, as we mentioned above, were associated with the insufficient duration of the procedure (about 5 minutes of microwave ablation) and large size of the cysts (13-17 cm).

After achieving first satisfactory results, we decided to perform RFA and MWA *in vivo* in patients with echinococcal liver disease, followed by surgical intervention in the volume of pericystectomy to assess morphological and cytological changes with preserved blood flow in the liver. According to the results of the data obtained, ablation in patients with echinococcal cysts demonstrated its effectiveness (evident destructive changes in the cyst walls), safety (no damage to large vascular and biliary structures).

All the collected data led us to the next part of the study: a comparative analysis of treatment results of using PAIR, RFA and MWA

techniques in patients with echinococcal liver disease. Effects of ablation treatment methods of parasitic cysts are comparable with the commonly used PAIR method, but lead to less complications, repeat operations and relapses within a year of observation.

Conclusion

The presented clinical and morphological substantiation of applying ablation treatment methods on echinococcal cysts, as well as a comparative analysis with the commonly used PAIR treatment method, demonstrated patient safety and effectiveness in relation to the hydatid process. Further application of these operations and prospective multicenter studies will allow the evaluation of long-term results.

Acknowledgements

We would like to thank the scientific department of Botkin Hospital for financing this study.

Conflict of interest

The authors declare that they have no conflict of interest.

References

1. Hao W, Vuitton L, Tuxun T, Jun L, Vuitton DA, Zhang WB, McManus DP. Echinococcosis in the 21st century. *Clin Microbiol Rev.* 2019;32:e0005-18.
2. Tuxun T, Zhang J Hui, Zhao J Ming, et al. World review of laparoscopic treatment of liver cystic echinococcosis-914 patients. *Int J Infect Dis.* 2014;24:43-50.
3. Gavara CG, López-Andújar R, Ibáñez TB, et al. Review of the treatment of liver hydatid cysts. *World J Gastroenterol.* 2015 Jan 1;21(1):124-131.
4. Shabunin A, Tavobilov M, Karpov A. Echinococcosis of the liver: evolution of surgical treatment. *Pirogov Russian Journal of Surgery.* 2021(5):95-103.
5. Musaev GH, Levkin VV, Sharipov RH. Modern trends in surgical treatment of liver echinococcosis. *Sechenov Med J.* 2018 Dec 30(4):78-84. (in Russian)
6. Clavien PA, Barkun J, De Oliveira ML, et al. The Clavien-Dindo classification of surgical complications: five-year experience. *Ann Surg.* 2009 Aug 1;250(2):187-96.
7. WHO Informal Working Group. International classification of ultrasound images in cystic echinococcosis for application in clinical and field epidemiological settings. *Acta Trop.* 2003 Feb 1;85(2):253-61.
8. Fancellu A, Perra T, Vergari D, et al. Management of complex liver cystic hydatidosis: challenging benign diseases for the hepatic surgeon: a case series report from an endemic area. *Medicine (Baltimore).* 2020 Nov 25;99(48):e23435.
9. Ikramov R, Zhavoronkova O, Botiraliyev A, et al. Modern treatment of the liver echinococcosis. *Vysokotekhnologicheskaya medicina.* 2020 Jul 7(2):14-27. (in Russian)
10. Ok ÜZ, Kilimcioglu AA, Özkol M. Türkiye’de İnsanlarda Kistik Ekinokokkoz. Cystic echinococcosis in humans in Turkey. *Mikrobiyol Bul.* 2020;54(3):510-22.
11. Rajesh R, Dalip DS, Anupam J, Jaisiram A. Effectiveness of puncture-aspiration-injection-reaspiration in the treatment of hepatic hydatid cysts. *Iran J Radiol.* 2013 Jun;10(2):68-73.
12. Patkowski W, Krasnodębski M, Grąt M, Masiór Ł, Krawczyk M. Surgical treatment of hepatic *Echinococcus granulosus*. *Gastroenterology Review/Przegląd Gastroenterologiczny.* 2017 Sep 30;12(3):199-202.
13. Sokouti M, Sadeghi R, Pashazadeh S, et al. A systematic review and meta-analysis on the treatment of liver hydatid cyst using meta-MUMS tool: comparing PAIR and laparoscopic procedures. *Arch Med Sci.* 2019 Mar 1;15(2):284-308.